

Case report

Open Access

Clasp knife in the gut: a case report

Chintamani*, Anuj Mishra and Dinesh Bhatnagar

Address: Department of Surgery, Vardhman Mahavir Medical College, Safdarjang Hospital, New Delhi 110029, India

Email: Chintamani* - chintamani7@rediffmail.com; Anuj Mishra - mrinal5@rediffmail.com; Dinesh Bhatnagar - chintamani@doctor.com

* Corresponding author

Published: 10 December 2003

Received: 26 September 2003

BMC Surgery 2003, 3:12

Accepted: 10 December 2003

This article is available from: <http://www.biomedcentral.com/1471-2482/3/12>

© 2003 Chintamani et al; licensee BioMed Central Ltd. This is an Open Access article: verbatim copying and redistribution of this article are permitted in all media for any purpose, provided this notice is preserved along with the article's original URL.

Abstract

Background: A wide range of foreign bodies has been retrieved from the gut and reported. The presentation may be in the form of complications like intestinal obstruction, perforation and formation of abscesses etc but there is no case report of a half open clasp knife being retrieved from the ileum, the patient having thrived, in spite of its presence for a period of eight months.

Case presentation: A 30-year-old administrative clerk had undergone emergency abdominal surgery eight months previously under mysterious circumstances at a remote district hospital and had recovered completely. Later the blade of a knife was accidentally detected when an X ray of the abdomen was done during a routine follow-up visit to his family physician. Surgery revealed a clasp knife in the ileum, which was retrieved. The presence of an entero-enteric fistula short circuiting the loop was the secret of his earlier survival.

Conclusions: To the best of our information this is the first case-report of a clasp knife in the gut and of the patient thriving in spite of its presence. We report here the dramatic sequence of events.

Background

A wide range of penetrating foreign bodies have been retrieved from the gut such as needles, toothpicks, blades, nails and pencils etc. [1-3]. The presentation may come as a radiological or an operative surprise if the history is not forthcoming. In the reported case the blade of a kitchen knife was detected as a radiological surprise.

Case Presentation

A 30 yr old administrative clerk presented to our outpatient department with the history of having undergone an abdominal operation for a blunt injury of the abdomen eight months previously at a remote rural district hospital. He recovered completely from the surgery except for occasional dyspeptic symptoms. During one of his routine visits to his family physician the presence of a knife blade

was detected on an Xray of the abdomen and he was referred to our tertiary care centre. On examination he was found to be anxious, but his vital signs were all within normal range. The abdomen showed a midline, well healed supple scar without an umbilicus. A repeat X-Ray of the abdomen (Fig. 1) was done, which was suggestive of a blade in the abdomen. The patient taken for an exploratory laparotomy which was done through a midline incision inclusive of the scar. Nearly 40 cm proximal to the ileocaecal junction an "M" loop of the small bowel was found fixed to the posterior abdominal wall. There was no evidence of any intestinal obstruction. The wooden hilt of a partially folded clasp kitchen knife was felt in the distal limb of the 'M' loop, whilst the blade was felt in the most proximal part, defunctioning the intermediate or middle loop of the bowel (Fig. 3). The knife was

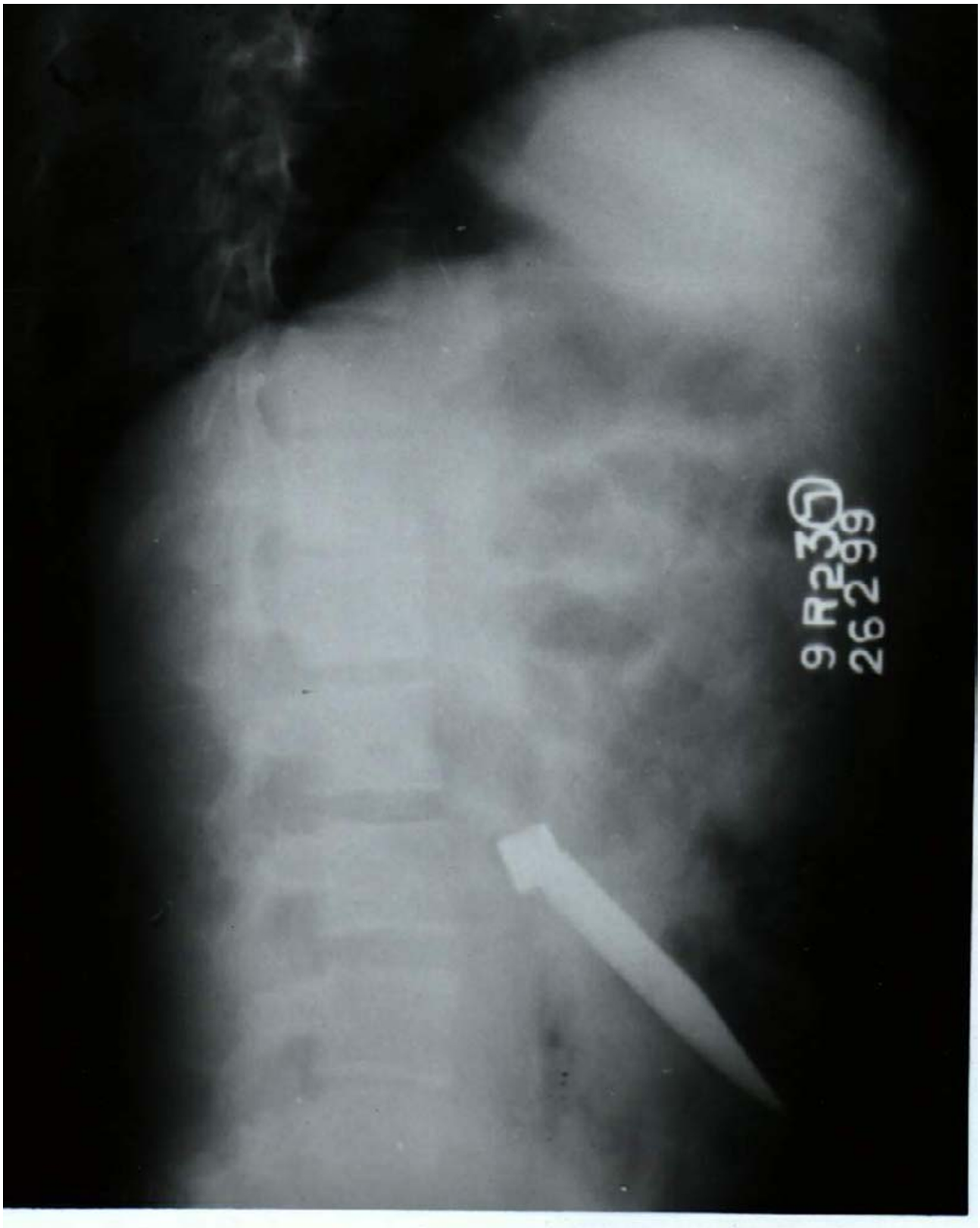

Figure 1
X-ray abdomen (lateral view) showing the blade of a knife in the abdomen.

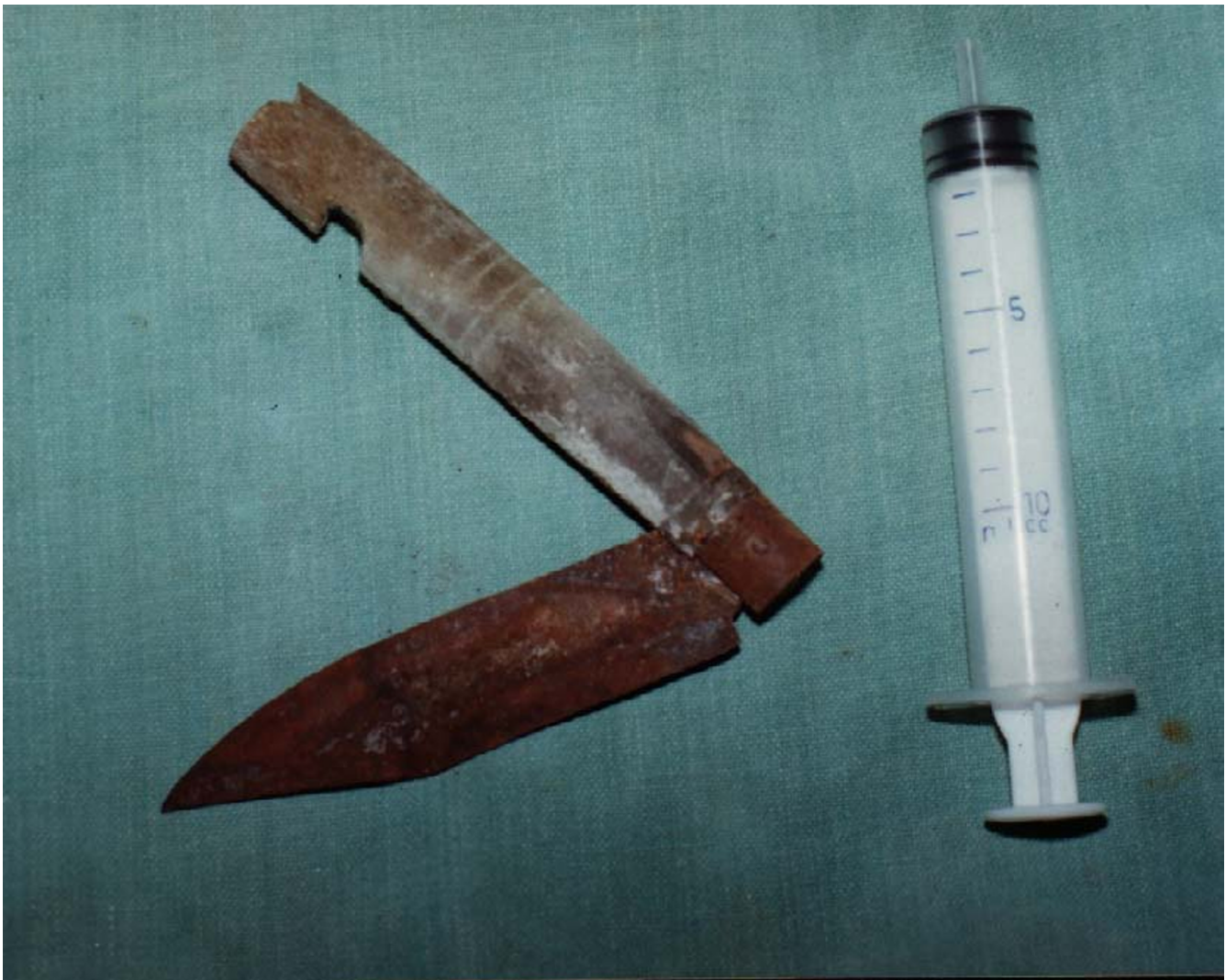


Figure 2
The retrieved clasp kitchen knife showing the position it was lying in.

straightened and retrieved after enterotomies to get hold of the hilt and blade respectively (Fig. 2). The 'M' segment of the bowel was resected and an end-to-end ileo-ileal anastomosis was performed. Dissection of the resected segment revealed the secret of his survival. There was a fistulous communication between the most proximal and the most distal limb of the "M" loop of the bowel, defuncting the intermediate loop. This was ensuring a free passage of the bowel contents and thus his survival. In the immediate postoperative period the father of the patient, and subsequently the patient himself, were persuaded to come out with the truth, and what they revealed was shocking. Nearly eight months previously, under the influence of "Bhasam"(an ash) given by a "tantrik"(a reli-

gious cult), our patient attempted killing his pregnant wife in order to retrieve the three months old foetus for performing some religious rites. Her parents rescued the lady in time. Having failed in his homicidal attempt, the patient pushed the same kitchen knife completely into his own abdomen, through his umbilicus, in the presence of his in-laws. He was rushed to the rural district hospital where a laparotomy was performed. However no operative details could be obtained in spite of repeated attempts.

Following the second operation his post-operative recovery was good. After discharge he recovered completely and uneventfully. He was subsequently treated at our

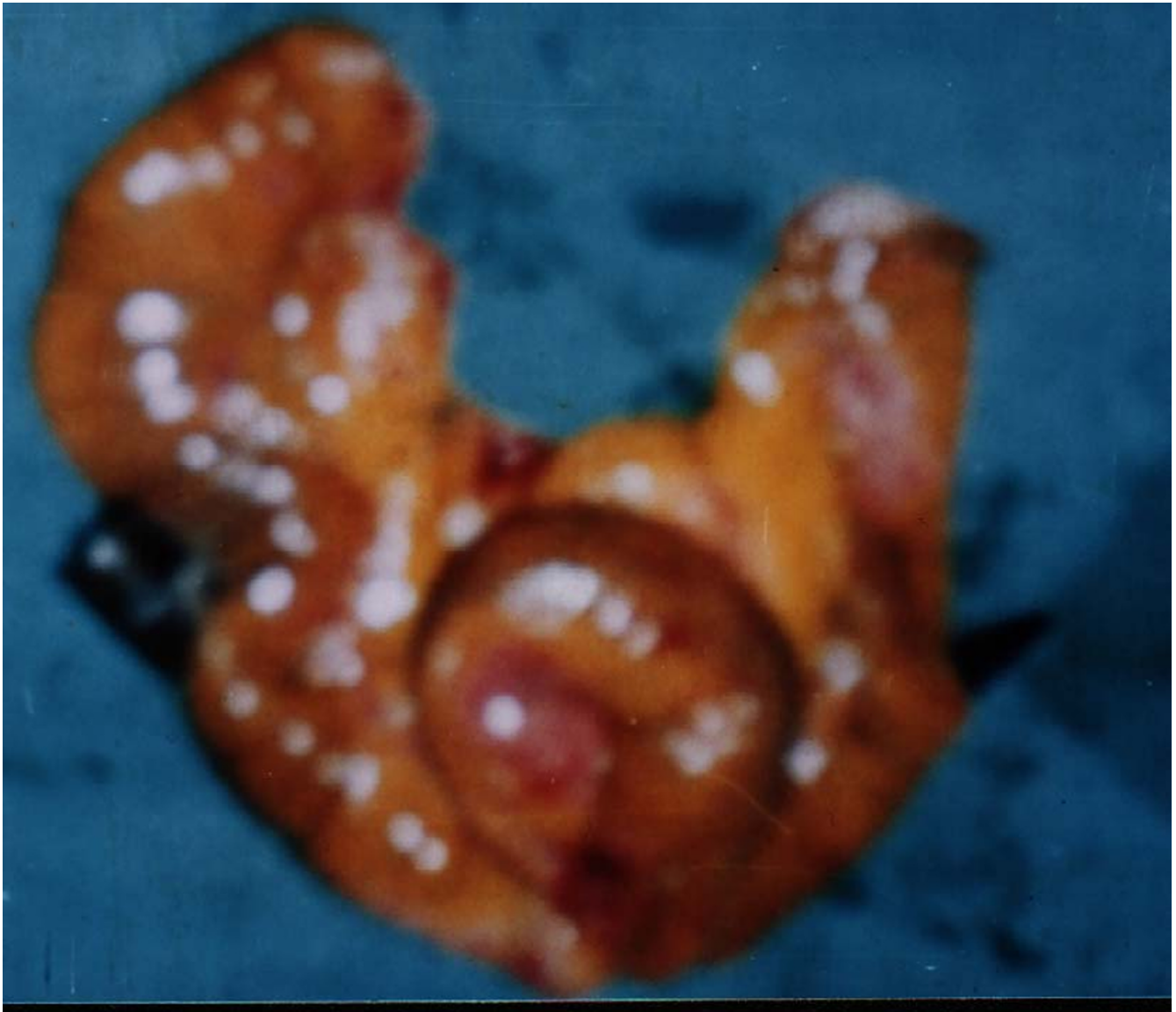

Figure 3

The "M" loop of the resected intestinal segment containing the clasp knife with the hilt in the proximal limb and blade of a knife in the distal limb.

psychiatric center for MDP (Maniac Depression Psychosis). Nearly two years of follow-up revealed a continued satisfactory recovery.

We were not able to find out how the knife was missed during the first operation. No details could be obtained from the district hospital except that an exploratory laparotomy was performed and the patient had had an uneventful recovery.

To the best of our information there is no case report of retrieval of a clasp (half-cocked) knife from the gut of a healthy individual, who was thriving well in spite of its presence for eight months.

This miraculous story of survival and the dramatic sequence of events reinforce the age-old belief that "life always finds its way".

Conclusions

A wide spectrum of foreign bodies retrieved from the gut has been reported [1-3] however the reported incidence of foreign bodies penetrating the gut is less than 1%, such objects being pointed or sharp in most of the cases, for example tooth picks, sewing needles, dental plates, fish and chicken bones etc. [1,3]. A foreign body in the gut may remain silent or may be detected incidentally during investigations. The diagnosis is usually straightforward if the patient reports with a history of incidental or accidental penetration of the abdomen by a foreign body. Otherwise an abdominal x-ray, or an ultrasound examination, or a computed tomographic scan may be required if the diagnosis is in doubt or if, as in this case, the history is not forthcoming [4-6]. A foreign body may also present as an associated complication like an abscess, a fistula or may migrate to sites like the liver etc.

This case is of interest because the presence of an internal entero-enteric fistula ensured a free passage of the intestinal contents in spite of the clasp knife obstructing the lumen, thus ensuring his survival.

Competing Interests

None declared.

Authors' contributions

Chintamani, the principal and corresponding author was the surgeon performing the surgery, Anuj was the first surgical assistant and Dinesh is the head of the unit and helped in the preparation of the manuscript.

Acknowledgements

A written consent was obtained from the patient regarding publication of the patient's details.

References

1. McCanse DE, Kurchin A, Hmshaw JR: **Gastrointestinal foreign bodies.** *Am J Surg* 1981, **142**:335.
2. Maleki M, Evans WE: **Foreign body perforation of the intestinal tract. Report of 12 cases and review of literature.** *Arch Surg* 1970, **102**:227-228.
3. Bloom RR, Nakano PH, Grey SW *et al.*: **Foreign bodies of the gastrointestinal tract.** *Am Surg* 1986, **52**:618-21.
4. Strauss JE, Balthazar FJ, Naidieh DP: **Jejunal perforation by a tooth pick: CT demonstration.** *J Comput Assist Tomogr* 1985, **9**:812-814.
5. Matsuzaki H, Kikuchi T, Ichinose M: **A case of granulomatous abscess of the liver due to penetration by fish bone (in Japanese).** *Nippon Shoukaki Geka Gakkaisi* 1995, **28**:1095-1099.
6. Gonzalez JG, Gonzalez RR, Patino JV: **CT finding in gastrointestinal perforation by ingested fish bones.** *J Comput Assist Tomogr* 1988, **12**:88-90.

Pre-publication history

The pre-publication history for this paper can be accessed here:

<http://www.biomedcentral.com/1471-2482/3/12/prepub>

Publish with **BioMed Central** and every scientist can read your work free of charge

"BioMed Central will be the most significant development for disseminating the results of biomedical research in our lifetime."

Sir Paul Nurse, Cancer Research UK

Your research papers will be:

- available free of charge to the entire biomedical community
- peer reviewed and published immediately upon acceptance
- cited in PubMed and archived on PubMed Central
- yours — you keep the copyright

Submit your manuscript here:
http://www.biomedcentral.com/info/publishing_adv.asp

