

Case report

Open Access

An unusual cause of small bowel obstruction: Gossypiboma – case report

Rasim Gencosmanoglu*¹ and Resit Inceoglu²

Address: ¹Department of Gastrointestinal Surgery, Marmara University Institute of Gastroenterology, Istanbul, Turkey and ²Department of General Surgery, Marmara University School of Medicine, Istanbul, Turkey

Email: Rasim Gencosmanoglu* - rgencosmanoglu@marmara.edu.tr; Resit Inceoglu - inceoglu@asg.com.tr

* Corresponding author

Published: 08 September 2003

Received: 30 April 2003

BMC Surgery 2003, 3:6

Accepted: 08 September 2003

This article is available from: <http://www.biomedcentral.com/1471-2482/3/6>

© 2003 Gencosmanoglu and Inceoglu; licensee BioMed Central Ltd. This is an Open Access article: verbatim copying and redistribution of this article are permitted in all media for any purpose, provided this notice is preserved along with the article's original URL.

Abstract

Background: The term "gossypiboma" denotes a mass of cotton that is retained in the body following surgery. Gossypiboma is a medico-legal problem especially for surgeons. To the best of our knowledge, the patient presented herein is the second reported patient in whom the exact site of migration of a retained surgical textile material into the intestinal lumen could be demonstrated by preoperative imaging studies.

Case presentation: A 74-year-old woman presented with symptoms of small bowel obstruction due to incomplete intraluminal migration of a laparotomy towel 3 years after open cholecystectomy and umbilical hernia repair. Plain abdominal radiography did not show any sign of a radio-opaque marker in the abdomen. However, contrast enhanced abdominal computerized tomography revealed a round, well-defined soft-tissue mass with a dense, enhanced wall, containing an internal high-density area with air-bubbles in the mid-abdomen. A fistula between the abscess cavity containing the suspicious mass and gastrointestinal tract was identified by upper gastrointestinal series. The presence of a foreign body was considered. It was surgically removed with a partial small bowel resection followed by anastomosis.

Conclusions: Although gossypiboma is rarely seen in daily clinical practice, it should be considered in the differential diagnosis of acute mechanical intestinal obstruction in patients who underwent laparotomy previously. The best approach in the prevention of this condition can be achieved by meticulous count of surgical materials in addition to thorough exploration of surgical site at the conclusion of operations and also by routine use of surgical textile materials impregnated with a radio-opaque marker.

Background

The term "gossypiboma" denotes a cotton foreign body that is retained inside the patient during surgery [1]. It has been reported to occur following surgical procedures such as abdominal, thoracic, cardiovascular, orthopedic, and

even neurosurgical operations [1–5]. Although the real incidence is unknown, it has been reported as 1 in 100 to 3000 for all surgical interventions and 1 in 1000 to 1500 for intraabdominal operations [6,7]. Nonspecific clinical symptoms and inconclusive imaging findings may

preclude an accurate diagnosis [8]. However, it can be diagnosed preoperatively in many instances with the help of radiological studies such as plain radiography when surgical textile materials have been impregnated with a radio-opaque marker, ultrasonography (USG), computerized tomography (CT), magnetic resonance imaging (MRI), and gastrointestinal contrast series [9–13]. Although some non-surgical approaches such as percutaneous radiological retrieval of foreign bodies are reported, they might either be unsuccessful or generate attendant complications [14]. Surgery is the most reliable method for removing foreign bodies especially from the abdomen. Development of a fistula to neighboring organs such as stomach, duodenum or intestine occurs infrequently [7,15,16]. The longer the retention time, the higher is the fistulization risk. Foreign bodies (e.g. surgical sponge) may completely migrate into the ileum without any apparent opening in the intestinal wall [17]. They usually cannot pass the ileocecal valve and cause complete intestinal obstruction at this level. However, if they can pass through this valve, they are easily discharged through the anus. On the other hand, if foreign bodies are too large (e.g. laparotomy towel) to move into the intestinal lumen, they cause bowel obstruction. We report a case with a retained laparotomy towel causing an acute mechanical intestinal obstruction due to its partial migration into the small bowel. To the best of our knowledge, this is the second reported patient in whom the exact site of migration of a retained surgical textile material into the intestinal lumen could be demonstrated by preoperative imaging studies after the first published case by Dux and associates [7].

Case presentation

A 74-year-old woman was admitted to the emergency unit with a history of colicky abdominal pain, nausea, and early postprandial vomiting. There was no remarkable abdominal distension on physical examination. She had undergone open cholecystectomy and umbilical hernia repair at another institution 3 years previously. One year later, an incisional hernia had been repaired by using a non-absorbable mesh at the same institution. She described a short febrile post-operative period following the initial surgery; however, there had been no fever for the last two years. The whole blood analysis showed a marked leukocytosis (white blood cells: 21,000 / mm³). Other biochemical parameters were within normal limits. The plain abdominal radiography did not show any sign of a radio-opaque marker in the abdomen. However, contrast enhanced abdominal computerized tomography revealed a round well-defined soft-tissue mass with a dense, enhanced wall containing an internal high-density area with air-bubbles in the mid-abdomen (Figure 1). Fistulization between the abscess cavity containing the suspicious mass and gastrointestinal tract at the level of

proximal jejunum was identified by upper gastrointestinal series (Figure 2). Marked dilatation of the proximal jejunal segments was noted. The presence of a foreign body was considered. At laparotomy, numerous dense adhesions between the small bowel and the non-absorbable (polypropylene) mesh were seen. Adhesions between the jejunal segment at 15 cm to the ligament of Treitz and the foreign body was observed; the small bowel mesentery had completely surrounded the foreign body. The jejunum was opened and one third of the towel was removed from the lumen. The rest was completely retrieved from the cavity (Figure 3). Intestinal continuity was established by end-to-end anastomosis following partial resection of the fistulized segment. The patient has been symptom-free in one year of follow-up.

Conclusions

The most common cause of small bowel obstruction in adults is adhesions due to the previous abdominal surgery. Gossypiboma is one of the rare causes of such an obstruction. Although it is an uncommon condition, it is the dread of every surgeon.

The diagnosis is easily made by plain abdominal radiography, when a radio-opaque marker is seen. However, this imaging method is not helpful when these markers are disintegrated or fragmented over time [18]. USG is another diagnostic tool which may well demonstrate foreign bodies. The presence of brightly echogenic wavy structures in a cystic mass showing posterior acoustic shadowing that changes in parallel with the direction of the ultrasound beam has been reported as a diagnostic feature of gossypiboma by Zbar and associates [18]. CT and MRI reveal comprehensive details about the mass in most cases. However, CT findings of gossypiboma, particularly in long standing cases, may be indistinguishable from intraabdominal abscess, since air bubbles and calcification of the cavity wall as well as contrast enhancement of the rim may be seen in both conditions [18,19]. MRI findings of the two cases reported by Kuwashima et al. [11] show that the center of the mass may have variable signal intensity that depends on the amount of the fluid and its protein content, while the thickened wall usually has low signal intensity on both T1- and T2-weighted images without remarkable gadolinium enhancement. When a fistula develops between the cavity containing the foreign body and the gastrointestinal lumen, contrast x-ray studies may reveal both the presence and the exact site of the fistula [7].

Once gossypiboma is diagnosed, it should be removed. Surgery had been the mainstay in the removal of the foreign bodies for many years. However, some reports recommending alternative methods have recently appeared in the literature. Noshier and Siegel [14] described six

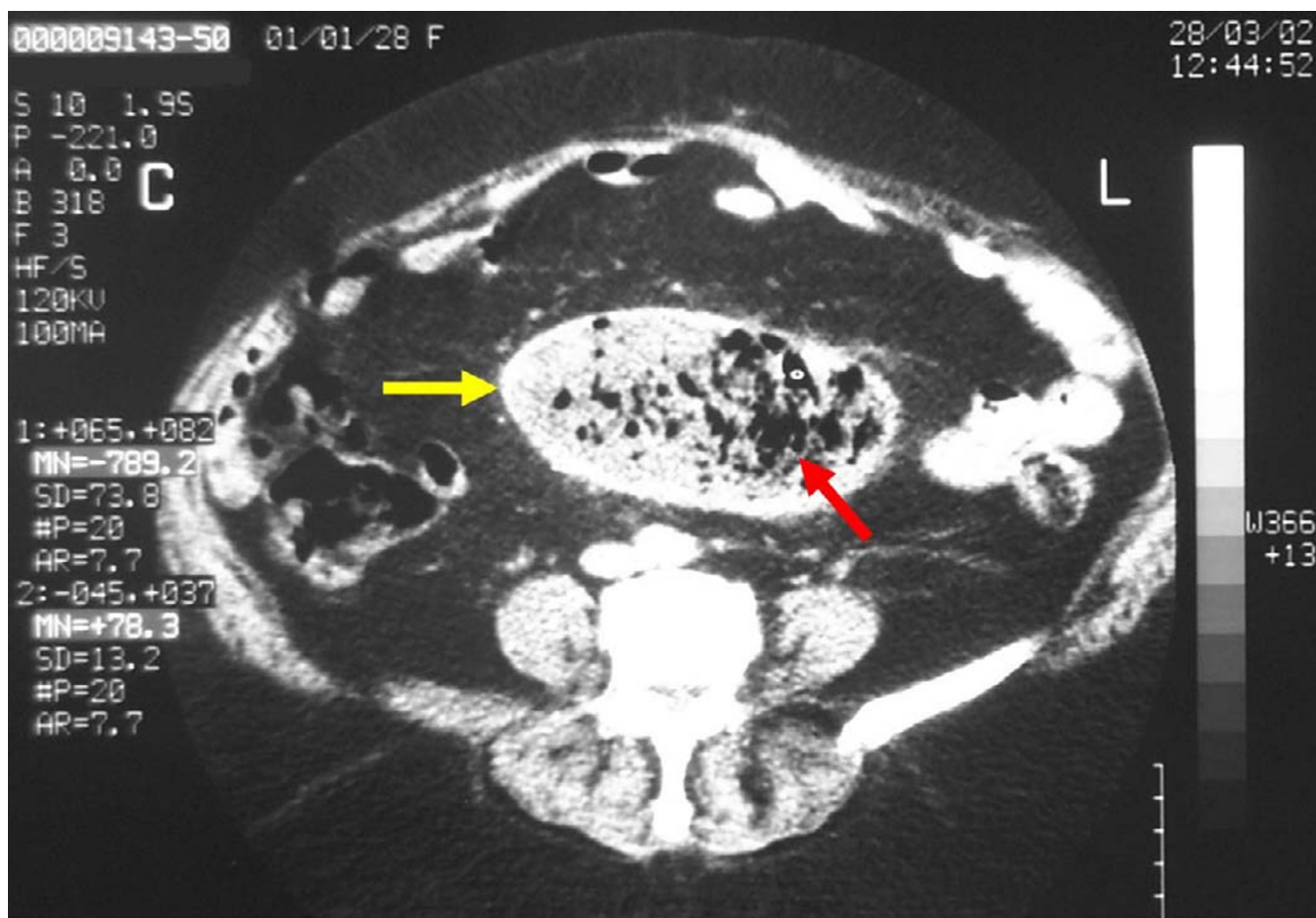


Figure 1
Computerized tomography appearance of a retained intraabdominal towel (yellow arrow). Note the air bubbles (red arrow) within the foreign body which absorbed the contrast agent.

patients in whom percutaneous extraction was successfully performed for removal of foreign bodies including an intraabdominal laparotomy towel, two pelvic drains, an angiographic guidewire fragment, and a superficially located sewing needle and bullet fragment. They concluded that this new method can obviate surgical incisions, extensive dissection, and the cost and risk of administration of general anesthesia. We believe that this method has little value for removal of retained foreign bodies from the abdomen, since the greater omentum, small intestine, and large intestine usually wall off foreign bodies. Additionally, it has been shown that there may be several dense adhesions between intraabdominal organs and foreign bodies at laparotomy. Moreover, if the initial surgery had been performed a long time before the diagnosis of gossypiboma, there may be a fistula between the cavity containing the foreign body and the gastrointesti-

nal tract as was the case in the presented patient. In this situation, resection of the affected segment is mandatory.

Besides many diagnostic and therapeutic difficulties, gossypiboma also carries some medico-legal implications. The presence of a foreign body inside the patient can be easily proved and the patient may litigate the responsible surgeon because this is an avoidable problem. Moreover, gossypiboma may be misdiagnosed as a malignant tumor and lead to unnecessary invasive diagnostic procedures or extensive extirpative surgery which may result in further complications [18].

Prevention is the best treatment as in many other medical problems. Avoidance of leaving foreign bodies inside the patients could be possible by implementation of three measures: 1. meticulous count of all surgical materials, 2.

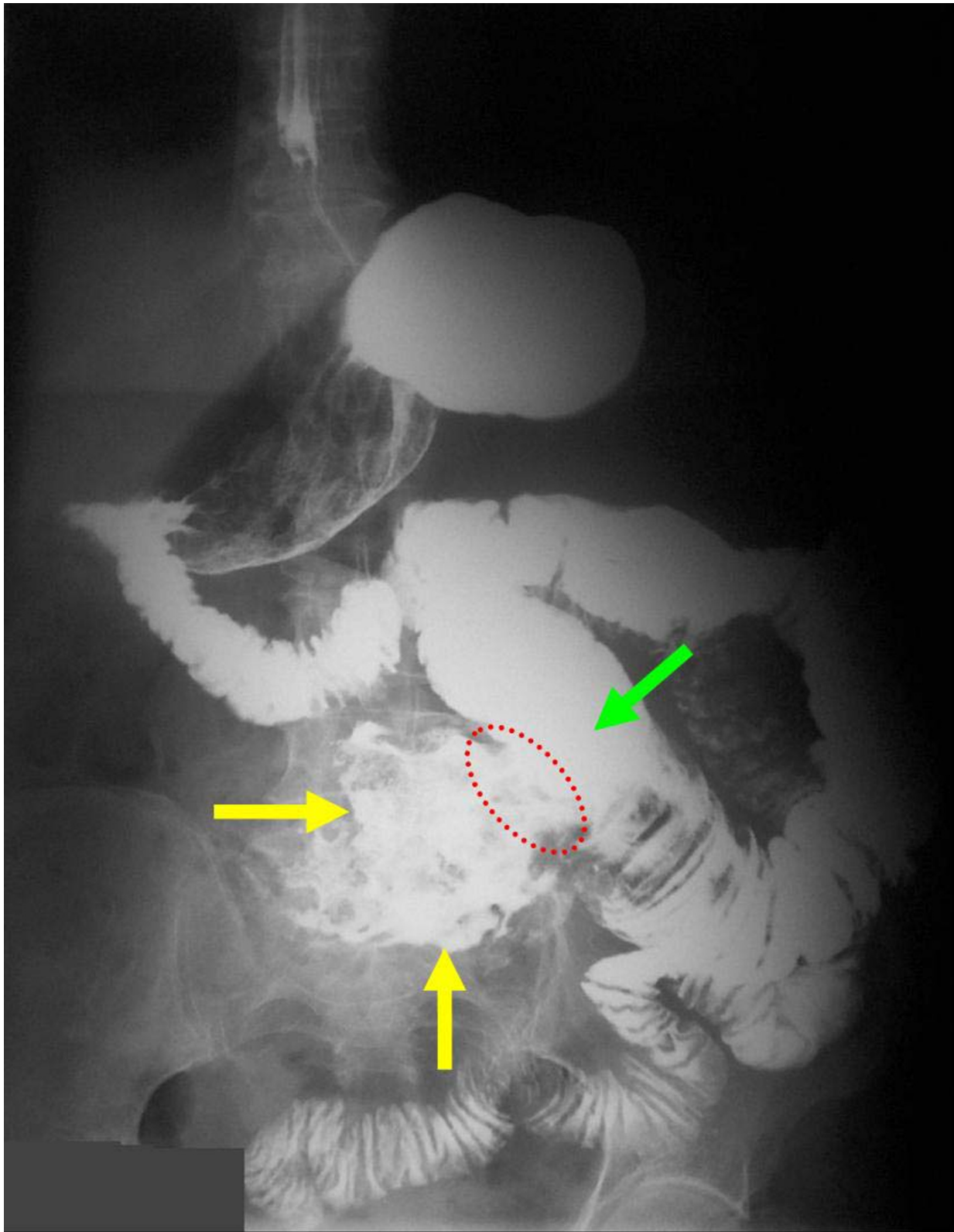


Figure 2
Upper gastrointestinal contrast study showed a fistula (red interrupted ring) between the cavity containing the foreign body (yellow arrows) and the jejunum (green arrow).



Figure 3
Retained laparotomy towel, 30 × 30 cm in size.

thorough exploration of the surgical site at the conclusion of the procedures, and 3. routine use of surgical textile materials impregnated with a radio-opaque marker.

All surgical textile materials and instruments should be counted once at the start and twice at the conclusion of surgical procedures. However, counts are not always sufficient, since most reported cases occur in spite of a normal pack count [18]. Dhillon and Park [16] reported a patient with retained laparotomy sponge 11 months after hysterectomy; the sponge count had been performed twice according to the operative record. The authors stressed the importance of a thorough exploration of four abdominal quadrants at the termination of surgical cases, since counts may be erroneous. Furthermore, the correct count can not be done in some instances, such as emergency

operations or an unexpected change in procedure, in which disorganization occurs. High body mass index of patients has been given as another risk factor [6]. On the other hand, when the accuracy of final count is in doubt, intraoperative radiologic screening may detect any retained surgical textile material impregnated with a radio-opaque marker. Moreover, Gawande et al. [6] suggested the routine radiographic screening of high-risk patients before they leave the operating room even when counts are documented as correct. Although marked swabs and packs are widely used by vast majority of surgeons, there is no uniform policy towards this practice in some Eastern and Central/Southern European countries. Nevertheless, gossypiboma is still a problem even in the countries where this policy is strictly adapted. Even though the surgeon carries the major responsibility, this

problem can only be overcome if all the members in an operation team work together meticulously as concluded by Schelhaas and Mastboom [20].

In summary, although gossypiboma is rarely seen in daily clinical practice, it should be considered in the differential diagnosis of acute mechanical intestinal obstruction in patients who underwent laparotomy previously. The best approach in the prevention of this condition can be achieved by meticulous count of surgical materials in addition to thorough exploration of surgical site at the conclusion of operations and also by routine use of surgical textile materials impregnated with a radio-opaque marker that are easily detected by intraoperative radiologic screening when the count is suspicious. Even though many alternative methods have been described for the removal of foreign bodies, we suggest that surgery should be performed in patients with abdominal gossypiboma, if the foreign body is deeply located and/or a fistula is present.

List of abbreviations used

USG – ultrasonography

CT – computerized tomography

MRI – magnetic resonance imaging

Competing interests

None declared.

Authors' contributions

RG participated in the operation and prepared the manuscript. RI performed the operation, read and approved the final manuscript.

Acknowledgements

Written consent was obtained from the patient for publication of study. The authors would like to thank Dr. Ilgin Ozden for the redaction of this article.

References

- Rajagopal A and Martin J: **Gossypiboma-"a surgeon's legacy": report of a case and review of the literature.** *Dis Colon Rectum* 2002, **45**:119-120.
- Sheehan RE, Sheppard MN and Hansell DM: **Retained intrathoracic surgical swab: CT appearances.** *J Thorac Imaging* 2000, **15**:61-64.
- Coskun M, Boyvat F and Agildere AM: **CT features of a pericardial gossypiboma.** *Eur Radiol* 1999, **9**:728-730.
- Mathew JM, Rajshekhkar V and Chandu MJ: **MRI features of neurosurgical gossypiboma: report of two cases.** *Neuroradiology* 1996, **38**:468-469.
- Abdul-Karim FW, Benevenia J, Pathria MN and Makley JT: **Case report 736: Retained surgical sponge (gossypiboma) with a foreign body reaction and remote and organizing hematoma.** *Skeletal Radiol* 1992, **21**:466-469.
- Gawande AA, Studdert DM, Orav EJ, Brennan TA and Zinner MJ: **Risk factors for retained instruments and sponges after surgery.** *N Engl J Med* 2003, **348**:229-235.
- Dux M, Ganten M, Lubienski A and Grenacher L: **Retained surgical sponge with migration into the duodenum and persistent duodenal fistula.** *Eur Radiol* 2002, **12**:74-77.
- Prasad S, Krishnan A, Limdi J and Patankar T: **Imaging features of gossypiboma: report of two cases.** *J Postgrad Med* 1999, **45**:18-19.
- Vayre F, Richard P and Ollivier JP: **Intrathoracic gossypiboma: magnetic resonance features.** *Int J Cardiol* 1999, **70**:199-200.
- Sahin-Akyar G, Yagci C and Aytac S: **Pseudotumor due to surgical sponge: gossypiboma.** *Australas Radiol* 1997, **41**:288-291.
- Kuwashima S, Yamato M, Fujioka M, Ishibashi M, Kogure H and Tajima Y: **MR findings of surgically retained sponges and towels: report of two cases.** *Radiat Med* 1993, **11**:98-101.
- Wan YL, Huang TJ, Huang DL, Lee TY and Tsai CC: **Sonography and computed tomography of a gossypiboma and in vitro studies of sponges by ultrasound. Case report.** *Clin Imaging* 1992, **16**:256-258.
- Apter S, Hertz M, Rubinstein ZJ and Zissin R: **Gossypiboma in the early post-operative period: a diagnostic problem.** *Clin Radiol* 1990, **42**:128-129.
- Nosher JL and Siegel R: **Percutaneous retrieval of nonvascular foreign bodies.** *Radiology* 1993, **187**:649-651.
- Mentes BB, Yilmaz E, Sen M, Kayhan B, Gorgul A and Tatlicioglu E: **Transgastric migration of a surgical sponge.** *J Clin Gastroenterol* 1997, **24**:55-57.
- Dhillon JS and Park A: **Transmural migration of a retained laparotomy sponge.** *Am Surg* 2002, **68**:603-605.
- Silva CS, Caetano MR, Silva EA, Falco L and Murta EF: **Complete migration of retained surgical sponge into ileum without sign of open intestinal wall.** *Arch Gynecol Obstet* 2001, **265**:103-104.
- Zbar AP, Agrawal A, Saeedi IT and Utidjian MRA: **Gossypiboma revisited: a case report and review of the literature.** *J R Coll Surg Edinb* 1998, **43**:417-418.
- Sheward SE, Williams AG Jr, Mettler FA Jr and Lacey SR: **Computerized tomography appearance of a surgically retained towel: gossypiboma.** *J Comput Assist Tomogr* 1986, **10**:343-345.
- Schelhaas E and Mastboom WV: **[A retained gauze as a cause of unexplained abdominal complaints].** *Ned Tijdschr Geneesk* 2002, **146**:241-245.

Pre-publication history

The pre-publication history for this paper can be accessed here:

<http://www.biomedcentral.com/1471-2482/3/6/prepub>

Publish with **BioMed Central** and every scientist can read your work free of charge

"BioMed Central will be the most significant development for disseminating the results of biomedical research in our lifetime."

Sir Paul Nurse, Cancer Research UK

Your research papers will be:

- available free of charge to the entire biomedical community
- peer reviewed and published immediately upon acceptance
- cited in PubMed and archived on PubMed Central
- yours — you keep the copyright

Submit your manuscript here:
http://www.biomedcentral.com/info/publishing_adv.asp

