

Technical advance

Open Access

## Modified capitonage in partial cystectomy performed for liver hydatid disease: Report of 2 cases

Dimitrios K Filippou\*<sup>1</sup>, Chariton Kolimpiris<sup>2</sup>, Nikolaos Anemodouras<sup>3</sup> and Spiros Rizos<sup>1</sup>

Address: <sup>1</sup>1st Surgical Department, Piraeus General Hospital "Tzaneion", Tzanni & Afentouli str, Piraeus Greece, <sup>2</sup>1st Surgical Department, Athens General Hospital "Agia Olga", 3-5 Agias Olgas str, Nea Ionia, Athens, Greece and <sup>3</sup>Department of General Surgery, Livadias General Hospital, Livadia, Greece

Email: Dimitrios K Filippou\* - d\_filippou@hotmail.com; Chariton Kolimpiris - webdocgr@hotmail.com; Nikolaos Anemodouras - anemos@otenet.gr; Spiros Rizos - srizos@otenet.gr

\* Corresponding author

Published: 28 June 2004

Received: 19 February 2004

BMC Surgery 2004, 4:8 doi:10.1186/1471-2482-4-8

Accepted: 28 June 2004

This article is available from: <http://www.biomedcentral.com/1471-2482/4/8>

© 2004 Filippou et al; licensee BioMed Central Ltd. This is an Open Access article: verbatim copying and redistribution of this article are permitted in all media for any purpose, provided this notice is preserved along with the article's original URL.

### Abstract

**Background:** Several techniques have been described in liver hydatid disease surgery, with most well known partial cystectomy, capitonage and introflexion.

**Methods:** We present a technical modification on open partial cystectomy for liver hydatid disease. We performed this operation in 2 patients with liver echinococcosis. The cyst is being unroofed and evacuated from the daughter cysts. The identified bile vessels ligated. The remnants of the anterior wall (capsule of the cyst) are anchored with sutures in the posterior wall in a manner that the cavity of the cyst disappears.

**Results:** In both patients the disease eradicated. No postoperative complications were observed including bile leaking and/or abscess formation.

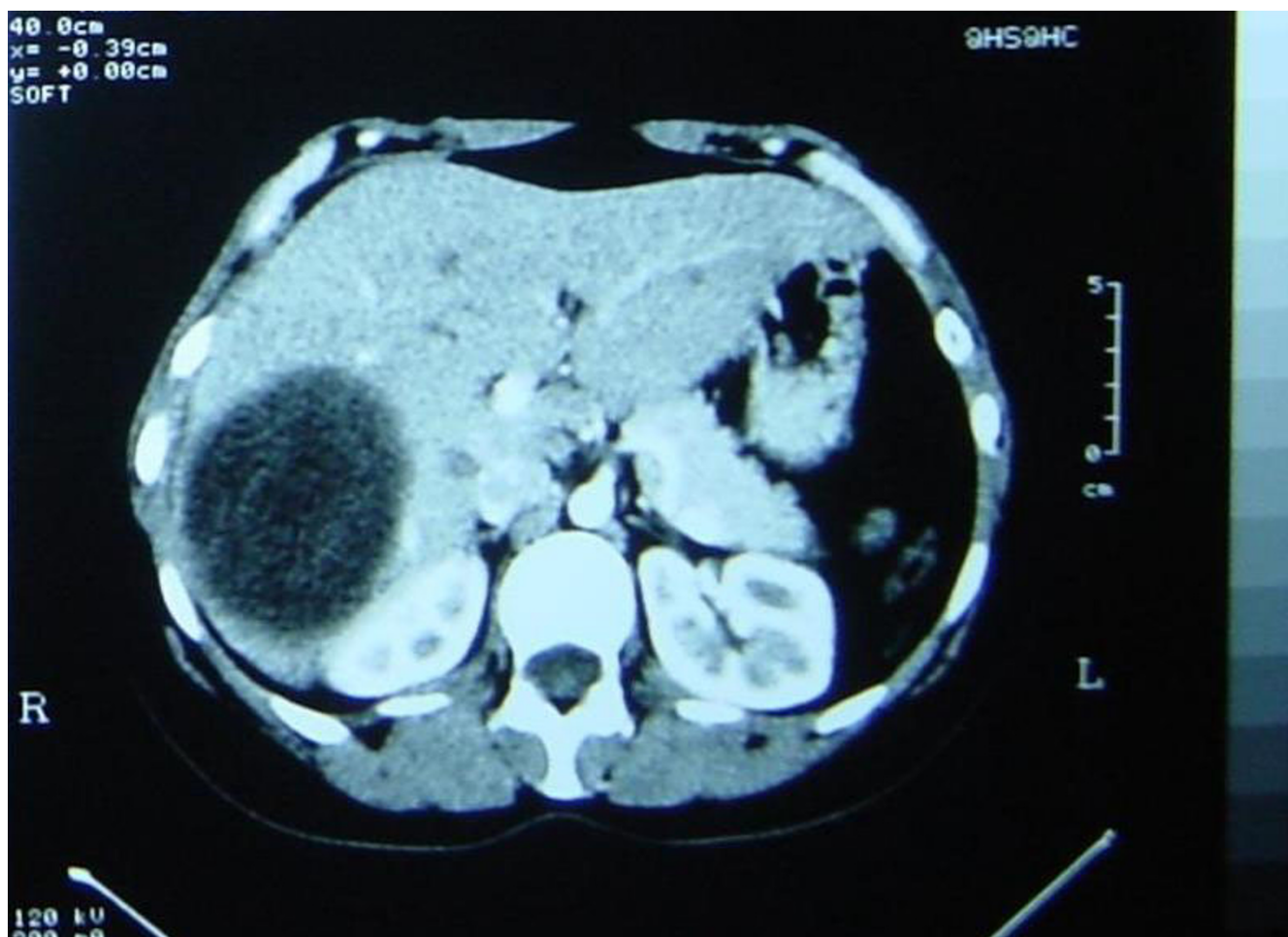
**Conclusions:** Our technique helps in the fast, and effective mobilization of the patient, as well as in the minimization of postoperative bile leaking.

### Background

Hydatid cyst is a parasitic disease caused by the tapeworm *Echinococcus granulosus* or *Ech. alveolaris*. The prevalence of the disease varies around the world. Hydatid disease is encountered in specific areas, as Mediterranean countries, Australia and New Zealand, South and Central America, Middle East, India and China [1].

Most common locations of the parasite infection are liver (60%) (Figure 1) and lungs (30%), while rarely cysts can be found in kidney, pericardium, brain and bones [2].

As far as medical therapy of hydatid disease has been disappointing, surgery remains the cornerstone in the treatment of this disease. Numerous surgical techniques have been proposed for liver disease. These include open and laparoscopic surgical techniques, while lately; mini-



**Figure 1**

Abdominal CT scan demonstrating a large right lobe hydatid cyst. You can also see the daughter cysts that are contained in the hydatid cyst. In the present slice the cyst's dimensions are 5 × 7 cm. The real size of the cyst as it was estimated in other slices estimated to 15 × 12 cm

mally invasive techniques have also been developed. PAIR (Percutaneous Aspiration Infusion Reaspiration technique), which belongs to the minimally invasive techniques, a real alternative to surgical procedures and chemotherapy, is of great value especially in cases where surgery and prolonged medical treatment with benzimidazoles is difficult or too expensive [3].

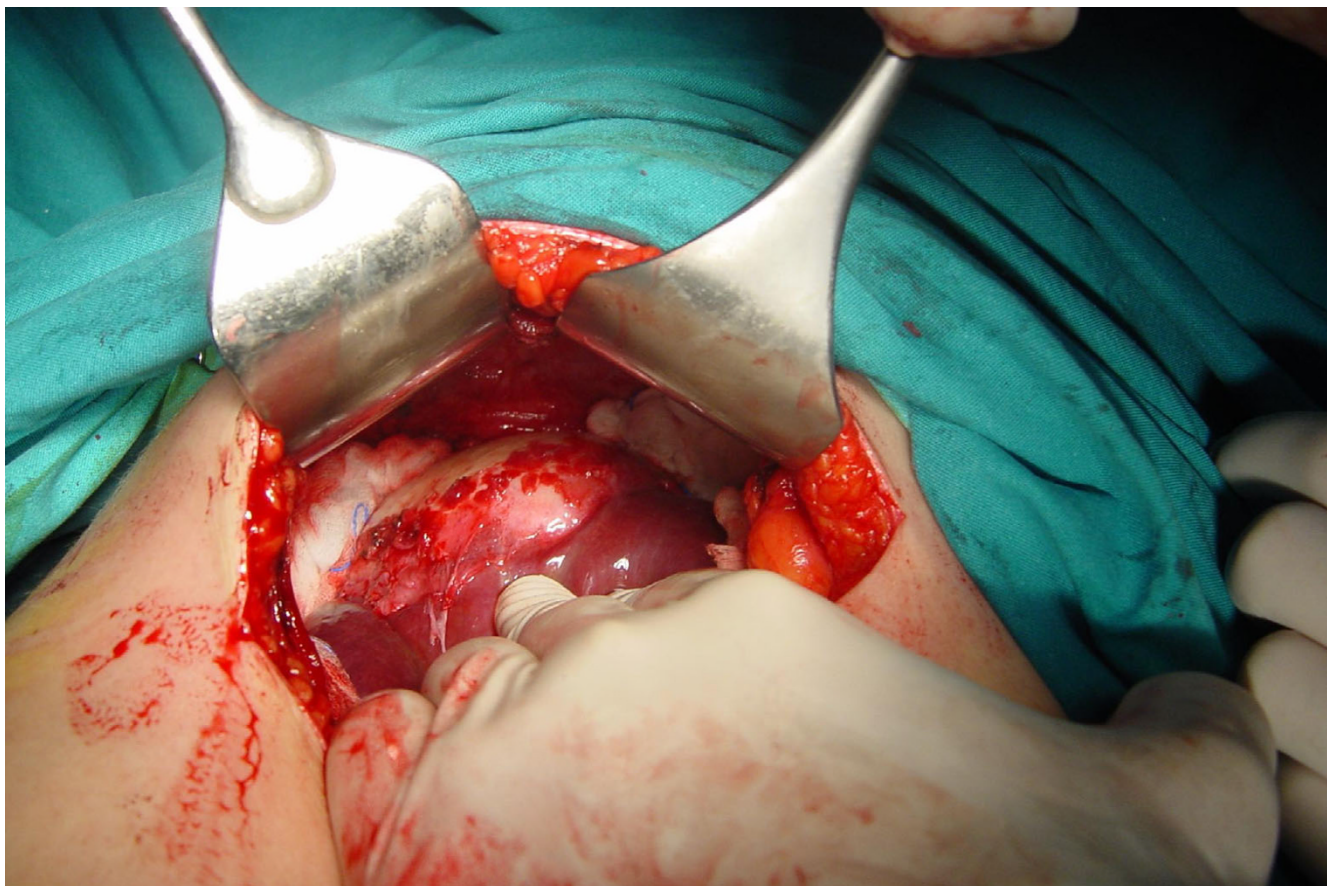
Classic open surgical techniques include ablation of the cyst, marsupialization, partial cystopericystectomy, subtotal pericystectomy, total pericystectomy and for large cysts liver resection (hepatectomy or segmentectomy) [4].

One of the major postoperative complications in liver hydatid disease surgery is bile leaking and the formation

of a "dead" space in which abscess is easy to develop. Our purpose was to minimize the "dead" space, which usually remains after cystectomy or partial cystectomy [5].

### Methods

For our technique we use a middle abdominal incision, from the xyphoid process until 4 cm below umbilicus, or extended right subcostal incision. After entering the abdominal cavity we examine the liver and the cyst (Figure 2). The surgical field is packed with sterile clean pads to reduce the risk of intraperitoneal soiling and contamination. The inner of the cyst is sterilized by infusion of hypertonic saline solution and chlorexidine. Then the hydatid cyst is opened and evacuated by aspiration with a closed system suction device (Figure 3).

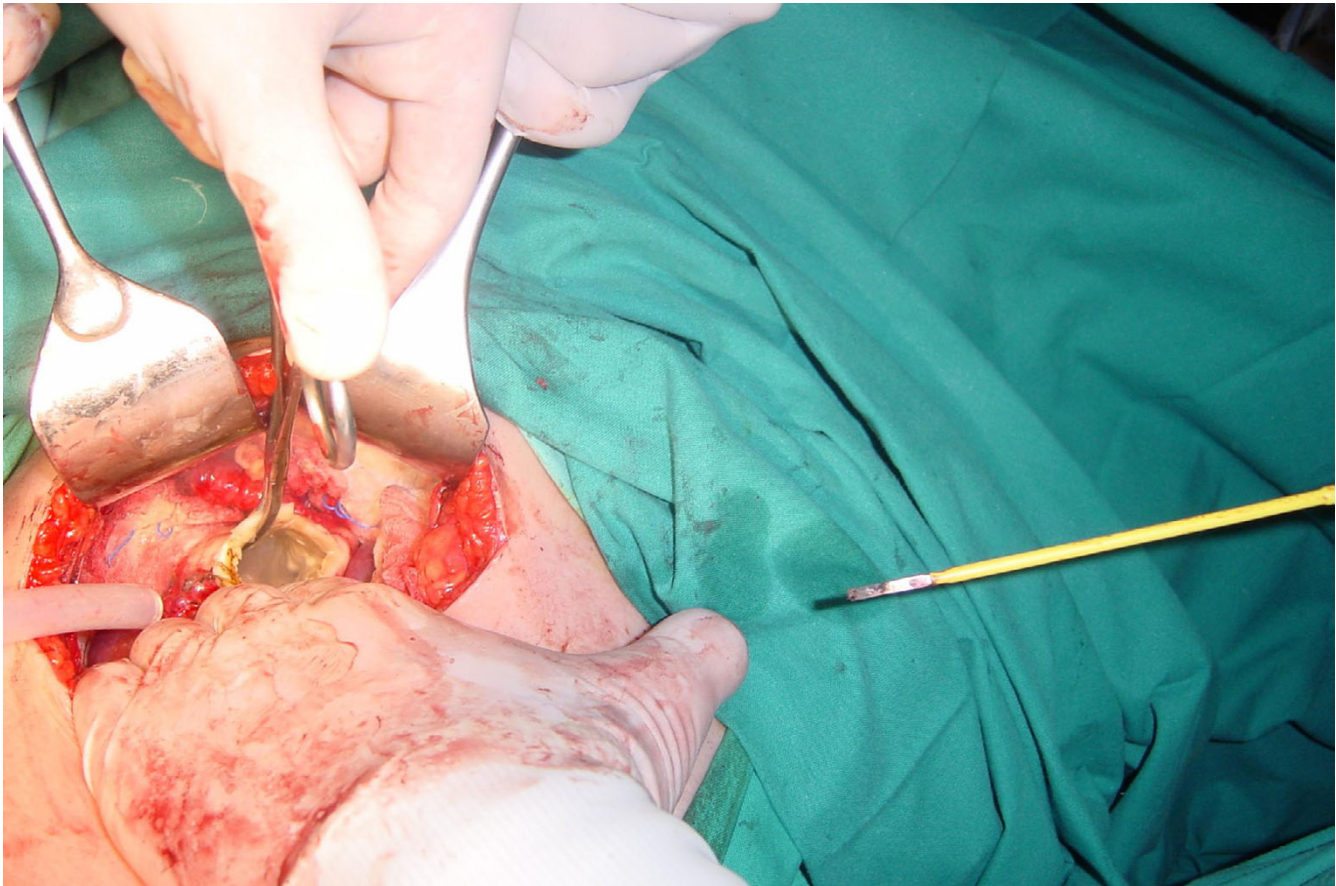


**Figure 2**  
After entering in the abdominal cavity with middle incision, the large right lobe hydatid cyst is identified.

The content of the cyst is examined to define if it is bilious or purulent. If biliary orifices are found they are sutured to avoid postoperative bile leaking. When the cyst is unroofed the remaining daughter cysts are separately removed. We put clean gauzes inside the cyst to identify bile leaking. If bile vessels revealed, they are ligated in order to avoid postoperative bile leaking. The remnant of the anterior wall of the cyst (capsule of the cyst) is sutured to the posterior wall, which is intact (Figure 4). More specific, each side of the anterior wall is anchored with absorbable sutures in the middle of the posterior wall. First we anchored the lateral edge of the anterior cystic wall, with several sutures. Then we continue with the medial edge in the same manner (Figure 5). With this kind of capitonage, the cavity of the cyst disappears. We usually put a silastic drainage tube to avoid possible fluid collection and prevent abscess formation (Figure 6). In our technique we avoid to use omentum for capitonage because of the referred complications [6].

## Results

We treated two patients with liver hydatid disease. One of them was male (58 years old, farmer), having a 15 cm diameter right-sided hydatid cyst (Figure 1). The other was a 62 years old female patient, with a 20 cm diameter left sided hydatid cyst. Both presented with mild symptoms (weight feeling, mild pain). The disease was diagnosed with computed tomography scan (CT), which demonstrated the cysts. Both of the patients had free medical history (no previous operations or severe illness requiring medical treatment). Our patients were treated with albendazole. Albendazole was administrated preoperatively (400 mg  $\times$  2) for a month and postoperatively (400 mg  $\times$  2) for three months. Although our cases were suitable for the PAIR procedure neither of these two patients were treated with PAIR because they refused and asked to be treated surgically. We conducted an open partial cystectomy including the proposed technical modification. In each one of the patients we found a biliary



**Figure 3**

The hydatid cyst is unroofed and evacuated by aspiration. Remaining daughter cysts are removed after repetitive infusions of hypertonic saline solutions and chlorexidine.

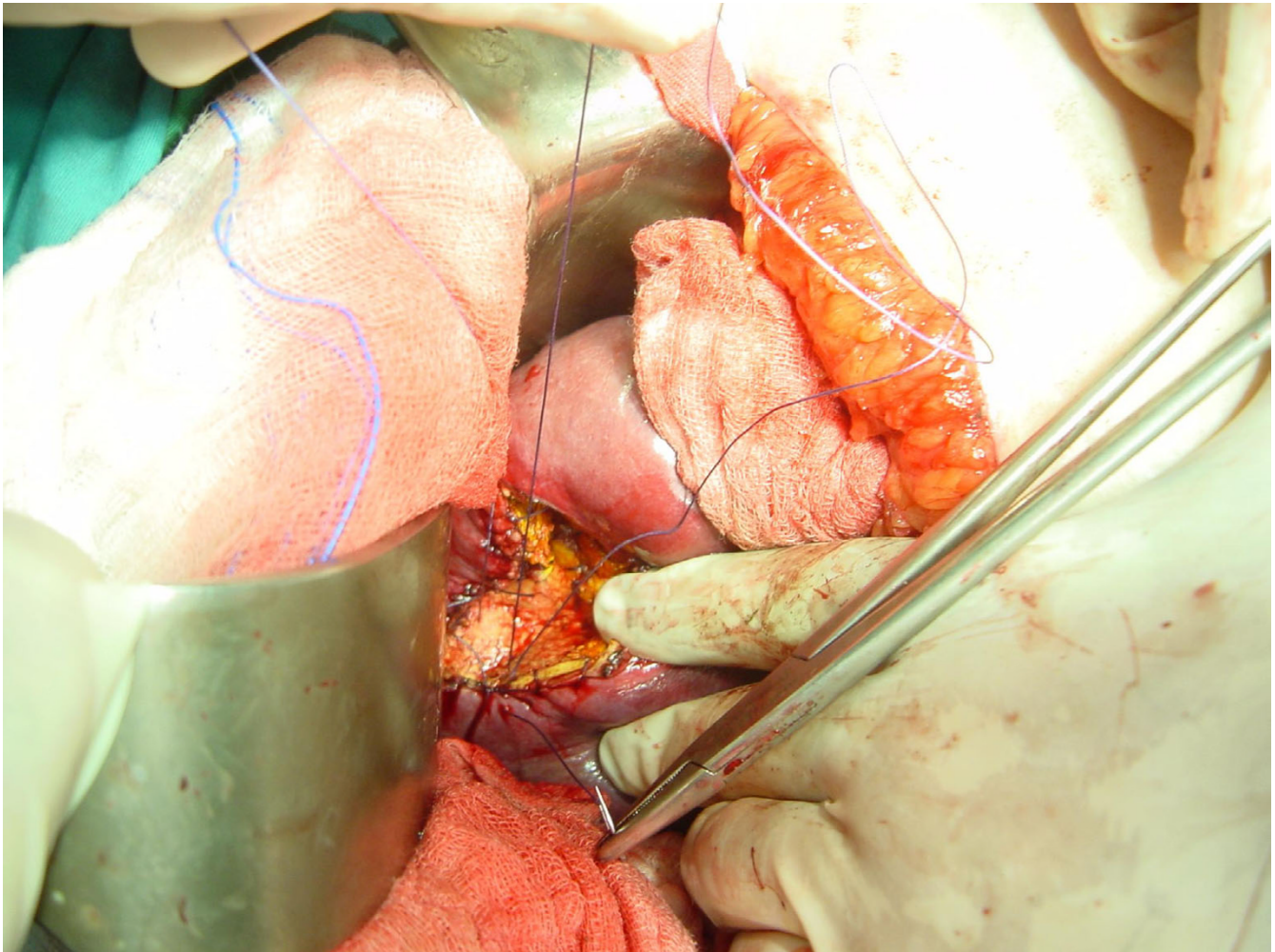
orifice, which was sutured. Neither of them presented postoperative complications including bile leaking. Postoperative examination of the formal cyst cavity with ultrasound failed to reveal fluid collection. The patients mobilized fast and quickly (mobilization started the 1<sup>st</sup> postoperative day) and they discharged the fourth and fifth postoperative day subsequently.

### Discussion

The most common techniques for liver hydatid disease treatment are marsupialization, partial cystopericystectomy with resection of the pericyst and subtotal pericystectomy by peeling the pericystium. The traditional surgical ablation of the cysts is still used by many surgeons all over the world, although the recurrence rate of this procedure is high and ranges from 10 to 30% [2,4-6].

*Marsupialization* was the most common used procedure because it is quick and safe, although is accompanied by a high rate of postoperative complications like residual cavity, disease soilage in biliary tract or intraperitoneal, bile leaking, vessels injuries and hemorrhage, sepsis, cholangitis and allergic shock [2,6]. For those reasons several technical improvements have been proposed, such as closing of all external communications of the cyst, and obliterating the remaining cyst with omentum or muscle flaps [7].

In *Partial Cystopericystectomy* not only the parasitic foci is eliminated but also the surrounded pericyst is removed. In this technique as in *subtotal pericystectomy*, small pericystic areas, which are located close to vascular and biliary vessels, are not resected because of the high risk for severe complications [8].



**Figure 4**

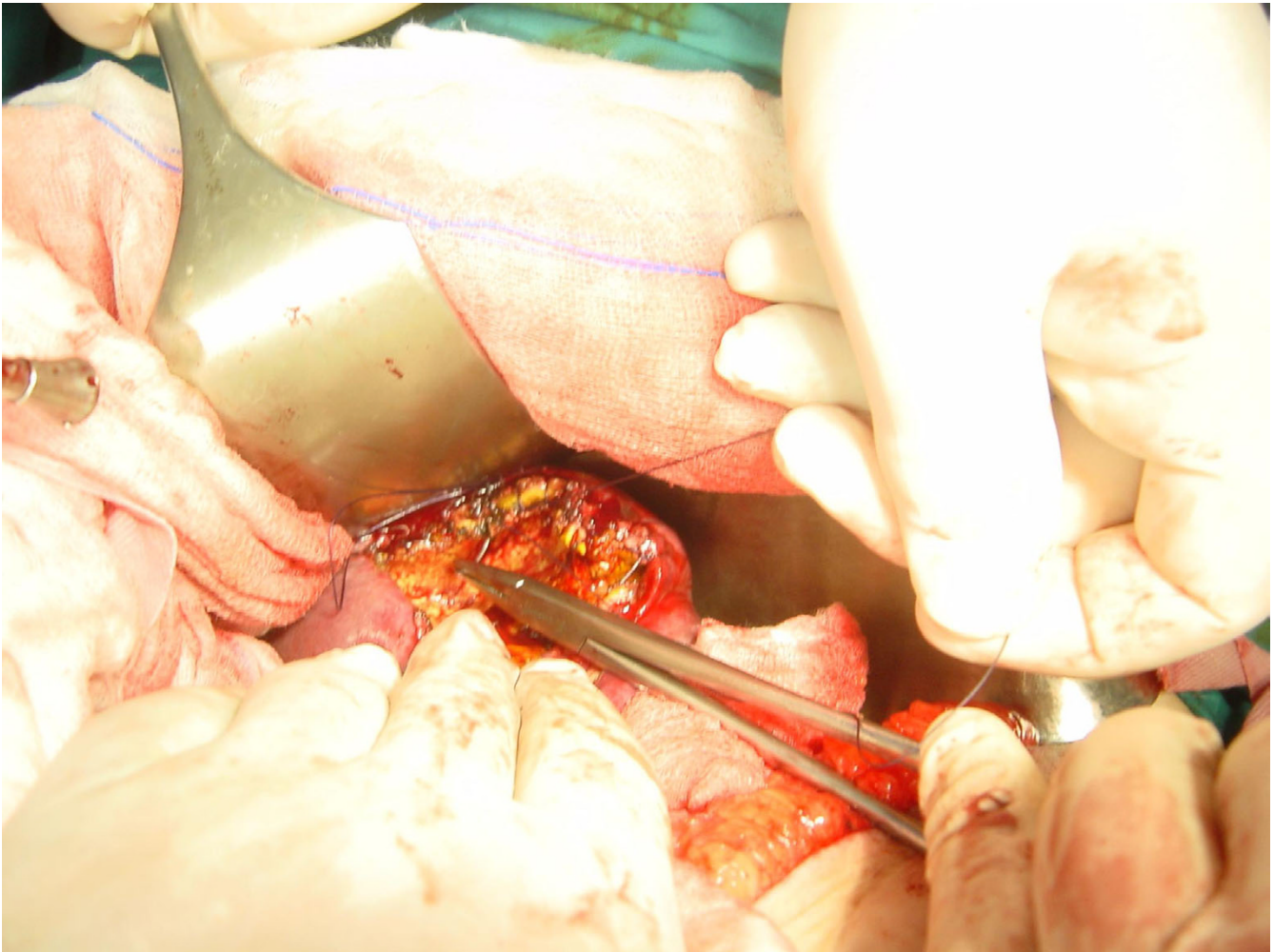
You can see the placement of the sutures in the lateral anterior edge of the cystic wall remnant. Then the interior edge is sutured and anchored in the posterior wall.

Finally in *radical operations* the parasitic content and the entire pericystic membrane is removed. In this subcategory the main procedures are total pericystectomy and liver resection. These operations are accompanied by increased morbidity and mortality [9].

All of the techniques applied in liver echinococcosis surgery present minor or major disadvantages and various postoperative complications. The method we propose is easy to perform, quick, safe and avoids most of the major postoperative complications, while eradicating the disease [10-12]. Although several authors suggest capitonage of the remaining cyst cavity, we avoid it because of the high incidence of postoperative necrosis of the omentum

and the development of septic complications [1]. Soiling and peritoneal contamination can be avoided with the simple prophylactic measures that every surgeon must apply in hydatid cyst surgery.

Some other authors suggest introflexion of the cyst. Our technique is a modified combination of capitonage and introflexion. It is well known that these techniques can be used without omentum. We propose a new alternative technique with good results, and it is easy to perform it. In cases that are complicated with postoperative bile leakage the "rosette-like" modified capitonage may facilitate the drainage easier than the "snail-like" introflexion. The



**Figure 5**

The capitonnage is completed when the edges of the anterior cystic wall remnants are sutured in the posterior wall. The capitonnage prevents the postoperative "dead" space, which facilitates the fluid collection.

results of the classic type of introflexion seem to be similar to ours, although the number of our patients is too small to allow comparison [13,14].

### Conclusions

We just describe our technical modification in these two patients. The efficacy of this method should be estimated in a large clinical trial.

In our cases we had no specific difficulties or method related complications. The only possible limitation of this technique may relate with the anatomic location of the hydatid cyst.

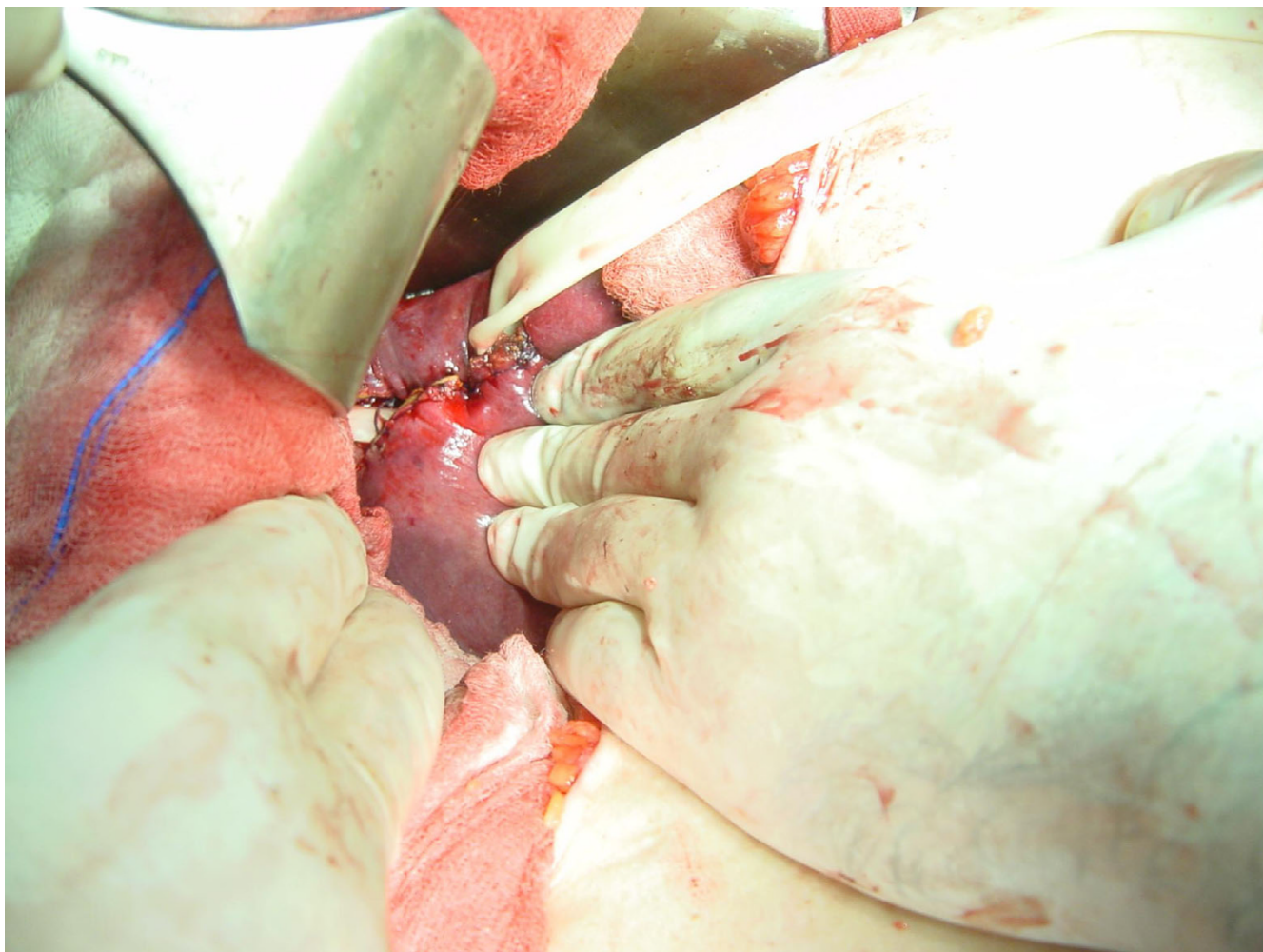
Concerning the bile dust and vessel injury, we do not use deep sutures that may cause vessel or bile duct injuries. Our sutures are not deep except from some fixation sutures. We also suggest avoiding deep sutures in locations close to hepatic vessels and inferior vena cava.

### Competing interests

None declared.

### Authors' contributions

All authors contributed equally to this work. All authors read and approved the final manuscript.



**Figure 6**

In the previous cavity of the cyst, under the capitonage, we place the drainage. The penrose drainage will be removed the 2<sup>nd</sup> postoperative day.

## Acknowledgments

We thank the patients for giving us written consent to present the recent study".

## References

1. Tselentis J, Karpathios T, Fretzayas A, Korkas A, Nicolaidou P, Matsaniotis N: **Hydatid disease in asymptomatic young carries in northern Greece.** *Am J Trop Med Hyg* 1983, **32**:1462-6.
2. Townsend CM, Beauchamp RD, Evers M, Mattox KL: **Sabiston. Textbook of Surgery. The biological basis of modern surgical practice** 16th edition. Edited by: Meyers WC, Kim RD, Chari RS. Harcourt International Edition: Echinococcal cysts; 2001:1053-56.
3. Gruttadauria S, Basile F, Marino G, Gentile A, Vittoria Sgroi AV, Gruttadauria G: **Development in diagnosis and treatment of hepatic echinococcosis in a surgical department of a Mediterranean center over a 20-years period.** *Ann Ital Chir* 2000, **71**:99-104.
4. Saglam A: **Laparoscopic treatment of liver hydatid cysts.** *Surg Laparosc Endosc* 1996, **6**:29-33.
5. Skroubis G, Vagianos C, Polydorou A, Tzoracoleftherakis E, Androulakis J: **Significance of bile leaking complicating conservative surgery for liver hydatidosis.** *World J Surg* 2002, **26**:704-8.
6. Demirci S, Eraslan S, Anadol E, Bozatli L: **Comparison of the results of different surgical techniques in the management of hydatid cyst of the liver.** *World J Surg* 1989, **13**:88-90.
7. Uravic M, Stimac D, Lenac T, Ivanis N, Petrosic N, Rubinic M, Skarpa A: **Diagnosis and treatment of liver hydatid disease.** *Hepatogastroenterology* 1998, **45**:2265-9.
8. Prousalidis J, Tzardinoglou E, Kosmidis C, Katsohis K, Aletras O: **Surgical management of calcified hydatid cysts of the liver.** *HPB Surg* 1999, **11**:253-9.
9. Cirenei A: **Hepatectomie pour kyste hydatique.** *Rev Int Hepatol* 1965, **15**:1325-8.
10. Cirenei A, Bertoldi I: **Evolution of surgery for liver hydatidosis from 1950 to today: analysis of personal experience.** *World J Surg* 2001, **25**:87-92.
11. Magistrelli P, Masetti R, Coppola R, Messina A, Nuzzo G, Picciocchi A: **Surgical treatment of hydatid disease of the liver: a 20-year experience.** *Arch Surg* 1991, **126**:518-22.

12. Utkan NZ, Canturk NZ, Gonullu N, Yildirim C, Dulger M: **Surgical experience of hydatid disease of the liver: omentoplasty or capitonnage versus tube drainage.** *Hepatogastroenterology* 2001, **48**:203-7.
13. Ariogul O, Emre A, Alper A, Uras A: **Introflexion as a method of surgical treatment for hydatid disease.** *Surg Gynecol Obstet* 1989, **169**:356-8.
14. Kayaalp C, Sengul N, Akoglu M: **Importance of cyst content in hydatid liver surgery.** *Arch Surg* 2002, **137**:159-163.

### Pre-publication history

The pre-publication history for this paper can be accessed here:

<http://www.biomedcentral.com/1471-2482/4/8/prepub>

Publish with **BioMed Central** and every scientist can read your work free of charge

*"BioMed Central will be the most significant development for disseminating the results of biomedical research in our lifetime."*

Sir Paul Nurse, Cancer Research UK

Your research papers will be:

- available free of charge to the entire biomedical community
- peer reviewed and published immediately upon acceptance
- cited in PubMed and archived on PubMed Central
- yours — you keep the copyright

Submit your manuscript here:  
[http://www.biomedcentral.com/info/publishing\\_adv.asp](http://www.biomedcentral.com/info/publishing_adv.asp)

