


RESEARCH

Open Access



Laparoscopic ventral mesh rectopexy vs. transperineal mesh repair for obstructed defecation syndrome associated with rectocele: comparison of selectively distributed patients

Bengi Balci¹, Sezai Leventoglu^{2*} , Igbal Osmanov¹, Beyza Erkan², Yasemin Irkilata³ and Bulent Mentesh¹

Abstract

Purpose Obstructed defecation syndrome represents 50–60% of patients with symptoms of constipation. We aimed to compare the two frequently performed surgical methods, laparoscopic ventral mesh rectopexy and transperineal mesh repair, for this condition in terms of functional and surgical outcomes.

Methods This study is a retrospective review of 131 female patients who were diagnosed with obstructed defecation syndrome, attributed to rectocele with or without rectal intussusception, enterocele, hysterocele or cystocele, and who underwent either laparoscopic ventral mesh rectopexy or transperineal mesh repair. Patients were evaluated for surgical outcomes based on the operative time, the length of hospital stay, operative complications, using prospectively designed charts. Functional outcome was assessed by using the Initial Measurement of Patient-Reported Pelvic Floor Complaints Tool.

Results Fifty-one patients diagnosed with complex rectocele underwent laparoscopic ventral mesh rectopexy, and 80 patients diagnosed with simple rectocele underwent transperineal mesh repair. Mean age was found to be 50.35 ± 13.51 years, and mean parity 2.14 ± 1.47 . Obstructed defecation symptoms significantly improved in both study groups, as measured by the Colorectal Anal Distress Inventory, Constipation Severity Instrument and Patient Assessment of Constipation-Symptoms scores. Minor postoperative complications including wound dehiscence ($n = 3$) and wound infection ($n = 2$) occurred in the transperineal mesh repair group.

Conclusion Laparoscopic ventral mesh rectopexy and transperineal mesh repair are efficient and comparable techniques in terms of improvement in constipation symptoms related to obstructed defecation syndrome. A selective distribution of patients with or without multicompartamental prolapse to one of the treatment arms might be the preferred strategy.

Keywords Obstructed defecation syndrome, Laparoscopic ventral mesh rectopexy, Transperineal mesh repair, Initial Measurement of Patient-Reported Pelvic Floor Complaints Tool

*Correspondence:

Sezai Leventoglu
sezailventoglu@hotmail.com

Full list of author information is available at the end of the article



© The Author(s) 2023. **Open Access** This article is licensed under a Creative Commons Attribution 4.0 International License, which permits use, sharing, adaptation, distribution and reproduction in any medium or format, as long as you give appropriate credit to the original author(s) and the source, provide a link to the Creative Commons licence, and indicate if changes were made. The images or other third party material in this article are included in the article's Creative Commons licence, unless indicated otherwise in a credit line to the material. If material is not included in the article's Creative Commons licence and your intended use is not permitted by statutory regulation or exceeds the permitted use, you will need to obtain permission directly from the copyright holder. To view a copy of this licence, visit <http://creativecommons.org/licenses/by/4.0/>. The Creative Commons Public Domain Dedication waiver (<http://creativecommons.org/publicdomain/zero/1.0/>) applies to the data made available in this article, unless otherwise stated in a credit line to the data.

Introduction

Obstructed defecation syndrome (ODS) is a disabling condition with major impact on quality of life. It was first described in 1978 as *outlet obstruction*, and eventually, it was included in the ROME IV criteria under the *functional anorectal disorders* section [1, 2]. Several underlying pathologies may cause ODS, including rectocele, rectal intussusception, pelvic floor dyssynergia, or slow-transit time constipation [3]. Patients with ODS usually suffer from straining, constipation, incomplete evacuation, and/or digitation to evacuate, with resultant changes in lifestyle [4].

Being a leading cause of ODS, rectocele is defined as a protrusion of the anterior rectal wall through the rectovaginal (RV) septum into the posterior vaginal wall, with well-known risk factors of elder age and multiparity [5, 6]. Besides, it is occasionally part of a multi-compartmental pelvic organ prolapse (PoP) associated with enterocele, cystocele or hysterocele, as also referred as *complex* rectocele [7]. Biofeedback therapy and dietary changes are the basis of the first-line treatment; however, surgery is indicated when these methods fail [8, 9].

Surgical treatment, whether transabdominal or transperineal/transvaginal/transanal, is based on the correction of rectal anatomy and function of the RV septum. Laparoscopic ventral mesh rectopexy (LVMR) has been reported to be a safe and feasible method for complex rectocele, and it has the advantage of correcting prolapse of other pelvic organs [7, 10]. Nonetheless, for patients with simple (predominant, isolated) rectocele, transperineal mesh repair (TPMR) has become our treatment of choice, with significant improvement in obstructed defecation symptoms [11].

In the present study, patients with ODS were stratified according to the diagnosis of complex or isolated, simple rectocele and designated for either LVMR or TPMR technique. The success of the two treatment methods with regard to ODS was targeted as the end point.

Material and methods

Study design and inclusion criteria

This study investigated a cohort of female patients who underwent LVMR or TPMR between May 2015 and July 2021 for ODS. This study is a retrospective review of patients' charts by a prospective evaluation using validated questionnaires. The study was performed in Memorial Ankara Hospital, and it was approved by the Ethics Committee (10.06.2021/02). The study was reported according to the STROBE guidelines [12].

Patients were recruited among those who had ODS and failed with conservative management, including dietary change and biofeedback therapy. Female

patients were deemed eligible for inclusion if they had anterior rectocele of Baden-Walker stages II-III [13], larger than 3 cm in size, and with one or more of the following symptoms: excessive straining, incomplete evacuation, the need for digitalization during defecation, and/or dyspareunia. Those who had a history of colorectal resection or rectocele repair, slow-transit time constipation, overt rectal prolapse, nonrelaxing puborectalis, sphincter injury, or inflammatory bowel diseases were excluded. The study investigated the outcomes in selectively distributed patient cohorts with clearly stated inclusion criteria.

In addition to colonoscopy, dynamic MRI defecography was performed in all patients to confirm the diagnosis and to reveal any concurrent pathology. Patients with a complex rectocele, which was defined as a rectocele above 3 cm with at least one additional pathology of rectal intussusception, enterocele, hysterocele or cystocele, underwent LVMR. On the other hand, TPMR was scheduled for the patients with a simple rectocele without any aforementioned pathology on MRI. Of the 144 patients who met the eligibility criteria, five patients in LVMR group and eight patients in TPMR group were lost follow-up. Two patients with complex rectocele were not suitable for the laparoscopic technique (chronic obstructive pulmonary disease and previous multiple abdominal operations), and they underwent combined perineal procedures with TPMR.

Study variables

Clinical features including the American Society of Anesthesiologists (ASA) classification [14], body mass index (BMI), parity, operative time, intraoperative and postoperative complications, and the length of hospital stay were noted. The postoperative complications were graded according to Clavien-Dindo classification, and grade III-IV-V complications were considered as major complications [15].

Initial Measurement of Patient-Reported Pelvic Floor Complaints Tool (IMPACT) is a combination of most-used scoring systems and scales regarding the pelvic floor disorders, and it was applied for the preoperative and postoperative 12th month's functional assessment [16]. *IMPACT: bowel function assessment tool, short form* is a particular domain of this tool which includes 45 questions for women and 34 questions for men, and it covers the following instruments: Bristol scale, Wexner Incontinence Score (WIS), St. Marks Incontinence Score (SMIS), Constipation Severity Instrument (CSI), Patient Assessment of Constipation-Symptoms (PAC-SYM), and Colorectal Anal Distress Inventory (CRADI).

Operative techniques

All operations were performed by or under the supervision of two experienced coloproctologists (SL, BM).

Laparoscopic ventral mesh rectopexy (LVMR)

The LVMR procedure was performed similar to the original technique described by D'Hoore [17] (Online resource 1). Bowel preparation with polyethylene glycol was done one-day prior to surgery. The patient was positioned in a Lloyd-Davies position under general anesthesia. Four trocars were inserted as follows: two 5 mm trocars from the left and right upper quadrants and two 10 mm trocars from the umbilicus and the right lower quadrant. The dissection was initiated with the opening of the pelvic peritoneum at the level of sacral promontory, and it was carried out to the pelvis with a reversed J-shaped form. The dissection was kept limited to the anterior of the rectum, and lateral or posterior dissection was avoided. Denonvillier's fascia was opened, and the dissection was continued until the pelvic floor muscles were exposed. The level of pelvic floor muscles was also confirmed with digital vaginal and rectal examination, intraoperatively. A polypropylene/polyglactin 910 mesh (Vypro[®], Johnson & Johnson Ethicon Inc., USA) of 3 × 15 cm was fashioned with a distal width of 3 cm tapering it to a proximal width of 2 cm to resemble a spatula. The mesh was placed anteriorly to the rectum and fixated by two 3/0 polydioxanone sutures (PDS II[®], Johnson & Johnson Ethicon Inc., USA) on each side of the rectum. Then, an adhesive material (LiquiBand[®]FIX8[™], Advanced Medical Solution, Plymouth, UK) was used to secure the mesh to the anterior wall of the rectum. Traction was applied, and then the upper edge of the mesh was fixated to the sacral promontory by titanium tacks (ProTack[™] 5 mm, Covidien, Minneapolis, MN). The pelvic peritoneum was approximated with continuous 3/0 V-Loc[™] (Medtronic Covidien, USA) sutures to cover the mesh. Pelvic drains were not placed in any patient.

Transperineal mesh repair (TPMR)

Spinal anesthesia was used for the majority of patients. In the lithotomy position, 15 ml of 1:2000 adrenaline solution was injected into the RV septum behind the posterior vaginal wall (Online resource 2). A transverse perineal incision was made, and a plane between the posterior wall of the vagina and the anterior wall of the rectum was developed up to the posterior fornix, using the cut mode of the electrocautery. A polyglycolic acid mesh (Soft PGA Felt[®], Aventis Behring GmbH, Germany), measuring approximately 8 × 4 cm, was tailored to fit on the defect. PGA mesh soaks blood and rapidly adheres to the tissues. No sutures or additional interventions were

used. Only the skin was approximated in an interrupted fashion with 3/0 polyglactin 910 sutures (Vicryl[®], Johnson & Johnson Ethicon Inc., USA).

Follow-up

Patients were followed up in the outpatient clinic at postoperative 1 and 3 months for any complications, and at 12 months for the study parameters by residents who were blinded to the study design. The anorectal and vaginal examinations were performed on each visit and the findings were recorded. The anatomical recurrence was defined as the failure of RV septum more than Baden-Walker stage I. The patients were also evaluated by using IMPACT at the postoperative 12th month.

Study endpoints

The primary endpoint was to compare these two procedures regarding treatment of ODS using IMPACT and anatomic healing. The secondary endpoints were differences in surgical outcomes, such as the operative time, operative bleeding, postoperative complications, and length of hospital stay.

Statistical analysis

The statistical software package SPSS 22.0 for Windows[®] (SPSS Inc., Chicago, IL) was used. Continuous variables were reported as mean with standard deviation if normally distributed, or median with range if abnormally distributed. Categorical variables were presented as frequencies with percentages. Continuous variables were compared using the Chi-square test. The comparative analysis of two study groups regarding IMPACT scores was done using the Kolmogorov–Smirnov test. The differences between preoperative and postoperative 12th month IMPACT scores within each group were analyzed using the Wilcoxon matched-pair signed-rank test. A *p*-value of < 0.05 was accepted as significant.

Results

A total of 131 female patients were included in the final analysis: 51 patients in the LVMR group and 80 patients in the TPMR group. Patients' clinical features are shown in Table 1. The leading symptoms declared by the patients were constipation (*n* = 68), straining (*n* = 30), feeling of incomplete evacuation (*n* = 15), rectal pain (*n* = 12), fecal incontinence (*n* = 6), although most patients complained from more than one.

Concomitant pathologies with rectocele found on MRI were enterocele (*n* = 9), hysterocele (*n* = 4), cystocele (*n* = 3), and rectal intussusception (*n* = 42). Additional procedures included transobturator tape (TOT), vaginal hysterectomy and/or primary cystocele repair for five patients in the LVMR group, and anterior colporrhaphy

Table 1 Patients' clinical features according to the study groups

Variables	Study cohort (n = 131) Mean ± SD or Median (Min–Max) or N(%)	LVMR (n = 51) Mean ± SD or Median (Min–Max) or N(%)	TPMR (n = 80) Mean ± SD or Median (Min–Max) or N(%)	p-value*
Age	50.35 ± 13.51 (24–87)	48.63 ± 11.41	51.45 ± 14.66	0.25
ASA				
I	83 (63.35)	34 (66.66)	49 (61.25)	0.67
II	44 (33.58)	15 (29.41)	29 (36.25)	
III	4 (3.05)	2 (3.92)	2 (2.5)	
BMI (kg/m ²)	24.96 ± 4.78 (18–40)	23.58 ± 4.57	25.85 ± 4.72	0.21
Parity	2 (0–10)	2 (0–4)	2 (0–10)	0.09
Operative time (minutes)	111.98 ± 42.77 (40–200)	151.37 ± 31.54	86.87 ± 27.21	0.000
Operative bleeding (ml)	6.62 ± 2.97 (3–20)	5.41 ± 2.06	7.40 ± 3.20	0.006
Clavien-Dindo				
I	3 (2.29)		3 (3.75)	0.045
II	2 (1.52)	-	2 (2.5)	
III	1 (0.76)		1 (1.25)	
Mean LOS (days)	1.10 ± 0.37 (1–4)	1.07 ± 0.27	1.12 ± 0.43	0.71
Mean Follow-up (months)	35.43 ± 17.09 (12–80)	29.01 ± 11.04	39.52 ± 18.97	0.21
Recurrence	3 (2.29)	2 (3.92)	1 (1.25)	0.31

Abbreviations: LVMR Laparoscopic ventral mesh rectopexy, TPMR Transperineal mesh repair, SD Standard deviation, N Number, ASA American Score of Anesthesiologists, BMI Body mass index, LOS Length of hospital stay

* p value was calculated with Chi-square test or Mann–Whitney U

with Kelly plication and TOT for two patients in the TPMR group. The mean operative time (induction to the recovery from anesthesia) was 151.37 ± 31.54 and 86.87 ± 27.21 min in LVMR and TPMR groups, respectively ($p=0.000$).

Minor postoperative complications occurred in five patients in the TPMR group: wound dehiscence in three patients and wound infection in two patients. A single major complication occurred and required surgical hemostasis on postoperative day-2 due to bleeding in the operative field. The mean length of hospital stay was 1.07 ± 0.27 and 1.12 ± 0.43 days in LVMR and TPMR groups, respectively ($p=0.71$). Anatomical recurrence was detected in three patients (LVMR; $n=2$ (3.92%), and TPMR; $n=1$ (1.25%)) during the mean follow-up of 35.43 ± 17.09 months.

The comparative analysis of preoperative and postoperative 12th month median IMPACT scores between the LVMR and TPMR groups revealed no differences, except for the preoperative CSI-pain subscale (Table 2). Further analysis within each group demonstrated statistically significant differences between the preoperative and postoperative 12th month median CRADI-8, CSI total, and PAC-SYM total scores as shown in boxplots (Fig. 1). The decreasing trend in postoperative Wexner

and SMIS scores did not reach statistical significance in either group.

The number of patients who had an improvement over 50% at postoperative 12th month's IMPACT scores were shown for each group in Table 3. In the LVMR group, 49 patients (96%) had statistically significant CRADI-8 ($p=0.021$) and PAC-SYM ($p=0.031$) improvements over 50% at postoperative 12th month.

The re-assessment of patients with continuing symptoms revealed failure of the RV septum in 3 patients and re-operation was offered. Biofeedback therapy and dietary changes with supplements were recommended for patients with obstructed defecation symptoms without any detectable anatomic failure.

Discussion

The present study demonstrates that LVMR and TPMR are efficient and comparable techniques in reconstructing the defective RV septum and alleviating constipation symptoms related to ODS. This is one of the few studies comparing a perineal approach with an abdominal/laparoscopic one for the treatment of ODS due to rectocele. Besides, the functional outcome was evaluated by the comprehensive tool IMPACT. The study, by definition, is not based on a randomized comparison,

Table 2 Comparison of preoperative and postoperative IMPACT scores in LVMR and TPMR groups

Variables	LVMR (n = 51) Median (Min–max)	TPMR (n = 80) Median (Min–max)	p-value*	LVMR (n = 51) Median (Min–max)	TPMR (n = 80) Median (Min–max)	p-value*
IMPACT scores	Preoperative			Postoperative 12 th month		
WIS	0 (0–19)	0 (0–20)	0.99	0 (0–15)	0 (0–20)	1.00
SMIS	0 (0–23)	0 (0–22)	0.99	0 (0–17)	0 (0–22)	0.93
CRADI-8	40.62 (13–84)	37.5 (22–88)	0.78	3.12 (0–38)	6.25 (0–78)	0.49
CSI Total score	57 (3–72)	59 (34–72)	0.96	5 (0–40)	8 (0–63)	0.08
CSI- ODS Subscale	22 (0–28)	22.5 (8–28)	1.00	3 (0–16)	4 (0–28)	0.13
CSI-Colonic Inertia Subscale	23 (1–29)	23 (15–29)	0.99	2 (0–20)	5 (0–26)	0.14
CSI- Pain Subscale	11 (2–16)	12 (3–16)	0.01	0 (0–7)	0 (0–12)	0.20
PAC-SYM	35 (3–47)	36 (22–48)	0.09	2 (0–30)	2 (0–38)	0.30
Total score						

Abbreviations: LVMR Laparoscopic ventral mesh rectopexy, TPMR Transperineal mesh repair, SD Standard deviation, WIS Wexner Incontinence Score, SMIS St. Marks Incontinence Score, CRADI-8 Colorectal Anal Distress Inventory, CSI Constipation Severity Instrument, PAC-SYM Patient Assessment of Constipation-Symptoms

* p value was calculated with Independent Kolmogorov–Smirnov (2 samples) test

and it examines and assesses the outcomes in selectively distributed patient cohorts with clearly stated inclusion criteria.

We reasonably treated our patients with *complex* rectocele with LVMR. Not infrequently, rectocele is part of a more complex PoP, associated with enterocele, cystocele, hysterocele, and/or rectal intussusception or rectal prolapse. In such a case, repairing only the rectocele by transperineal, transanal, or transvaginal route would inevitably be an inadequate procedure. On the other part, LVMR, as a modern approach, has its own limitations, and an ideal treatment algorithm for ODS due to rectocele is still debatable. Our results might provide further evidence for the developing algorithm for the treatment of ODS due to rectocele. The selective distribution of the patients to groups such as LVMR, TPMR, biofeedback, and excluded cases with additional pathologies results in modest number of cases in some groups with potential impact on sample size.

LVMR has been commonly preferred in patients presented with ODS in case of rectal intussusception with or without enterocele and rectocele [18]. We obtained good anatomical and functional results with LMVR in our selected group of patients with *complex* rectocele that support findings from previous studies [19–21]. The perineal descent, thus overall pelvic floor function only improves after ventral rectopexy, presumably as the result of additional pulling effect on the levator muscles. Moreover, better long-term functional outcomes with LVMR compared to perineal approaches is one of the advantages of this technique [22–24]. Similarly, we have found that more patients had an improvement in CRADI-8 and PAC-SYM scores over 50% at postoperative 12th month in the LVMR group.

This result might be attributed to more lasting effects of ventral rectopexy over transperineal repair, which is similar to comparative outcomes of this technique over STARR (stapled transanal rectal resection) in long-term [23].

It's also remarkable that we experienced no major complications after LVMR. However, the operation requires, anterior dissection of the rectum down to the levator muscles, and complications such as bladder injury have been reported [7]. Some cases may need to be converted to laparotomy because of complications or technical difficulties. A BMI > 35 and possible comorbidities in elderly patients might be additional limitations for a laparoscopic procedure. LVMR takes significantly longer than TPMR and any other anal/perineal procedures reported [7, 20]. Therefore, we need an alternative method for the treatment of rectocele even if the growing trend to and the satisfactory results with LVMR continue.

We have gained wide experience with the surgical treatment of rectocele, and a large series of us reporting the results of TPMR for rectocele was reported in 2007 [11]. Compared with this previous series of ours, our presents results are even better, possibly due to better patient selection and experience. Our results revealed that in selected patients, TPMR compares favorably with LVMR to treat ODS due to rectocele. Although we work from two completely different perspectives, we restore the defective RV septum successfully. As suggested by Watson and coworkers, mesh repair of rectocele deals with the cause (failure of the rectovaginal septum) rather than the effect [25]. The PGA mesh is easy to handle, and it helps surgical hemostasis in a highly vascularized tissue plane, also it attracts strong connective tissue rapidly

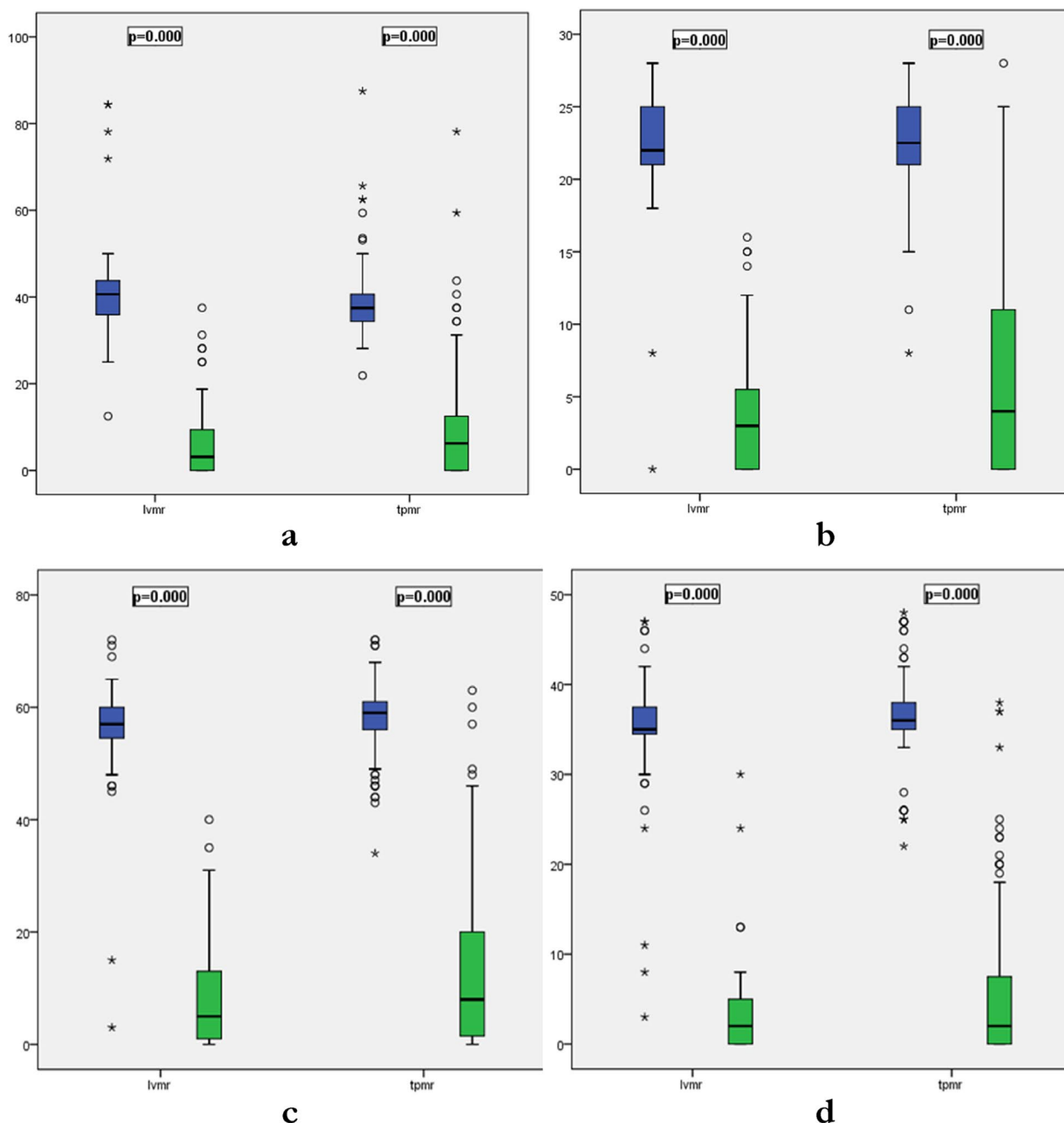


Fig. 1 Differences between preoperative and postoperative 12th month median IMPACT scores within each group: CRADI-8 scores are presented in (a), CSI-ODS Subscale scores in (b), CSI total scores in (c), and PAC-SYM total scores in (d). Note that p values reflect the differences in preoperative and postoperative CRADI-8, CSI-ODS and CSI scores within each group and the comparisons of outcomes between study group are presented in Table 2. *p* value was calculated with Wilcoxon matched-pair signed-rank test

to the defective RV septum. We've never encountered mesh reaction or mesh protrusion with the PGA mesh although we are well aware of the dramatic cases of mesh reaction and the timidity of surgeons to use a mesh, especially within the pelvis.

An alternative approach to TPMR is a transvaginal repair. Ferrari et al. reported global improvement of symptoms in 87.9% of patients, while ODS-related symptoms improved in only 58% [26]. A randomized-controlled trial on transperineal and transvaginal approaches revealed

Table 3 Number of patients with an improvement over 50% at postoperative 12th month's IMPACT scores

Variables	Patients' improvement N (%)		p-value
	LVMR (n=51)	TPMR (n=80)	
IMPACT scores			
WIS	4 (36)	3 (25)	0.55
SMIS	4 (33)	2 (16)	0.34
CRADI-8	49 (96)	66 (82)	0.021
CSI Total score	46 (90)	63 (78)	0.08
CSI-ODS Subscale	44 (86)	60 (75)	0.12
CSI-Colonic Inertia Subscale	43 (84)	60 (75)	0.20
CSI-Pain Subscale	50 (98)	73 (91)	0.11
PAC-SYM Total score	49 (96)	67 (83)	0.031

Abbreviations: LVMR Laparoscopic ventral mesh rectopexy, TPMR Transperineal mesh repair, SD Standard deviation, WIS Wexner Incontinence Score, SMIS St. Marks Incontinence Score, CRADI-8 Colorectal Anal Distress Inventory, CSI Constipation Severity Instrument, PAC-SYM Patient Assessment of Constipation-Symptoms

that constipation scores significantly decreased in both groups with no difference regarding recurrences [27]. Interestingly, increased resting and squeeze anal pressures were only found after transperineal repair.

Nevertheless, tailoring surgery for patients with ODS and considering the “iceberg diagram” for this unique condition have become the new rationale [28]. As well as the simplicity and complexity of the rectocele, the sphincter function is also one of the determinant factors in choosing the right technique [29]. Transperineal repair is usually preferred in patients with simple rectocele and poor sphincter function, whereas transanal and transvaginal repairs are preferred in cases with good sphincter function. On the other hand, a trend toward LVMR is seen in patients with complex rectocele regardless of the sphincter function.

The major drawback of our study appears to be non-randomized selection of patients for each procedure; however, possible co-existence of other organ prolapses, inevitably results in a selective distribution. Large number of patients with simple rectocele in our series is probably due to the selective admission of patients with ODS to our

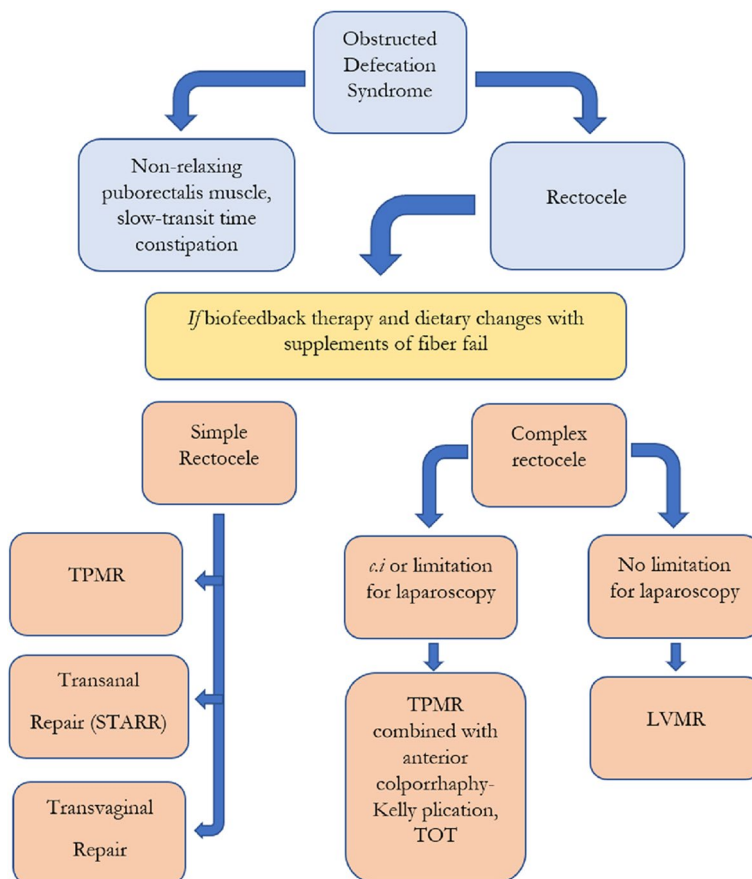


Fig. 2 Suggested-algorithm for patients with obstructed defecation syndrome attributed to rectocele. Abbreviations: LVMR, laparoscopic ventral mesh rectopexy; TPMR, transperineal mesh repair; STARR, stapled transanal rectal resection; TOT, transobturator tape

Proctology Unit, while patients with multicompartamental PoP are treated by gynecologists or urologists, too.

In conclusion, our strategy is to *i*) differentiate patients with rectocele according to the presence or absence of other compartmental prolapse, *ii*) treating complex rectocele with LVMR unless technical difficulties or contraindications for laparoscopy exist, and *iii*) treating simple rectocele with TPMR. Patients with complex rectocele and not suitable for laparoscopic technique may need TPMR+additional perineal/vaginal procedures such as anterior colporrhaphy and TOT (Fig. 2).

Supplementary Information

The online version contains supplementary material available at <https://doi.org/10.1186/s12893-023-02206-0>.

Additional file 1.

Acknowledgements

Not applicable.

Authors' contributions

All authors contributed to the study conception and design. The operations were carried out by or under the supervision of two senior proctologists (BM, SL). Material preparation, data collection and analysis were performed by Bengi Balci, Igbal Osmanov, Beyza Erkan and Yasemin Irkilata. The manuscript was written by Bengi Balci, Sezai Leventoglu and Bulent Menten, and all authors commented on the last version of the manuscript. All authors read and approved the final manuscript.

Funding

No fundings were received for this study.

Availability of data and materials

The datasets generated during and/or analyzed during the current study are available from the corresponding author on reasonable request.

Declarations

Ethics approval and consent to participate

All procedures performed in studies involving human participants were in accordance with the ethical standards of the institutional and/or national research committee and with the 1964 Helsinki Declaration and its later amendments or comparable ethical standards. The study was approved by the Ethics Committee of Memorial Ankara Hospital (10.06.2021/02), Ankara, Turkey. Informed consent was obtained from all subjects.

Consent for publication

Not applicable.

Competing interests

The authors declare no competing interests.

Author details

¹Department of Surgery, Memorial Ankara Hospital, Proctology Unit, Ankara, Turkey. ²Department of Surgery, Faculty of Medicine, Gazi University Hospital, Ankara, Turkey. ³Pelvic Floor Diseases Rehabilitation Clinic, Ankara, Turkey.

Received: 25 May 2023 Accepted: 24 September 2023
Published online: 24 November 2023

References

- Martelli H, Devroede G, Arhan P, Duguay C. Mechanisms of idiopathic constipation: outlet obstruction. *Gastroenterology*. 1978;75:623–31.
- Rao SS, Bharucha AE, Chiarioni G, Felt-Bersma R, Knowles C, Malcolm A, et al. Functional anorectal disorders. *Gastroenterology*. 2016;150(6):143–1442. <https://doi.org/10.1053/j.gastro.2016.02.009>.
- Pescatori M, Spyrou M, Pulvirenti d'Urso A. A prospective evaluation of occult disorders in obstructed defecation using the 'iceberg diagram'. *Colorectal Dis*. 2007;9:452–6. <https://doi.org/10.1111/j.1463-1318.2006.01094.x>.
- Altomare DF. ODS score and obstructed defecation. *Dis Colon Rectum*. 2010;53:363. <https://doi.org/10.1007/DCR.0b013e3181cbf35b>.
- Zbar AP, Lienemann A, Fritsch H, Beer-Gabel M, Pescatori M. Rectocele: pathogenesis and surgical management. *Int J Colorectal Dis*. 2003;18:369–84. <https://doi.org/10.1007/s00384-003-0478-z>.
- Dietz HP, Steensma AB. The role of childbirth in the aetiology of rectocele. *BJOG*. 2006;113:264–7. <https://doi.org/10.1111/j.1471-0528.2006.00860.x>.
- Wong M, Meurette G, Abet E, Podevin J, Lehur PA. Safety and Efficacy of Laparoscopic Ventral Mesh Rectopexy for Complex Rectocele. *Colorectal Dis*. 2011;13:1019–23. <https://doi.org/10.1111/j.1463-1318.2010.02349.x>.
- Zimmermann EF, Hayes RS, Daniels IR, Smart NJ, Warwick AM. Transperineal rectocele repair: a systematic review. *ANZ J Surg*. 2017;87(10):773–9. <https://doi.org/10.1111/ans.14068>.
- Bocchini R, Chiarioni G, Corazziari E, Pucciani F, Torresan F, Alduini P, et al. Pelvic floor rehabilitation for defecation disorders. *Tech Coloproctol*. 2019;23(2):101–15. <https://doi.org/10.1007/s10151-018-1921-z>.
- Abdelnaby M, Fathy M, Abdallah E, Balata M, Arnous M, Mikhail HM, et al. Laparoscopic ventral mesh rectopexy versus transvaginal posterior colporrhaphy in management of anterior rectocele. *J Gastrointest Surg*. 2020. <https://doi.org/10.1007/s11605-020-04823-z>.
- Leventoglu S, Menten BB, Akin M, Karen M, Karamercan A, Oguz M. Transperineal rectocele repair with polyglycolic acid mesh: a case series. *Dis Colon Rectum*. 2007;50:2085–92. <https://doi.org/10.1007/s10350-007-9067-5>.
- von Elm E, Altman DG, Egger M, Pocock SJ, Götzsche PC, Vandenbroucke JP, et al. The Strengthening of Reporting of Observational Studies in Epidemiology (STROBE) Statement: guidelines for reporting observational studies. *Int J Surg*. 2014;12(12):1495–9. <https://doi.org/10.1016/j.ijsu.2014.07.013>.
- Baden WF, Walker TA. *Surgical Repair of Vaginal Defects*. Philadelphia: Lippincott; 1992. p. 161–74.
- Doyle DJ, Goyal A, Bansal P, Garmon EH (2021) American Society of Anesthesiologists Classification. In: StatPearls. Treasure Island (FL): StatPearls Publishing; 2021 Jan.
- Dindo D, Demartines N, Clavien PA. Classification of surgical complications: a new proposal with evaluation in a cohort of 6336 patients and results of a survey. *Ann Surg*. 2004;240(2):205–13. <https://doi.org/10.1097/01.sla.0000133083.54934.ae>.
- Bordeianou LG, Anger JT, Boutros M, Birnbaum E, Carmichael JC, Connell KA et al. (2020) Measuring Pelvic Floor Disorder Symptoms Using Patient-Reported Instruments: Proceedings of the Consensus Meeting of the Pelvic Floor Consortium of the American Society of Colon and Rectal Surgeons, the International Continence Society, the American Urogynecologic Society, and the Society of Urodynamics, Female Pelvic Medicine and Urogenital Reconstruction. *Dis Colon Rectum* 63(1):6–23. <https://doi.org/10.1097/DCR.0000000000001529>.
- D'Hoore A, Penninckx F. Laparoscopic Ventral Recto(colpo)Pexy for Rectal Prolapse: Surgical Technique and Outcome for 109 Patients. *Surg Endosc*. 2006;20:1919–23. <https://doi.org/10.1007/s00464-005-0485-y>.
- Picciariello A, O'Connell PR, Hahnloser D, Gallo G, Munoz-Duyos A, Schwandner O et al. (2021) Obstructed defaecation syndrome: European consensus guidelines on the surgical management. *Br J Surg* 23;108(10):1149–1153. <https://doi.org/10.1093/bjs/znab123>.
- Altomare DF, Picciariello A, Memeo R, Fanelli M, Digennaro R, Chetta N, et al. Pelvic floor function following ventral rectopexy versus STARR in the treatment of obstructed defecation. *Tech Coloproctol*. 2018;22(4):289–94. <https://doi.org/10.1007/s10151-018-1776-3>.
- Madbouly KM, Mohii AD. Laparoscopic ventral rectopexy versus stapled transanal rectal resection for treatment of obstructed defecation in the elderly: long-term results of a prospective randomized study. *Dis Colon Rectum*. 2019;62(1):47–55. <https://doi.org/10.1097/DCR.00000000000001256>.

21. Mandovra P, Kalikar V, Patankar RV. Laparoscopic ventral mesh rectopexy for obstructive defecation syndrome: Follow-up in the Indian population. *J Min Access Surg.* 2021;17:305–10. https://doi.org/10.4103/jmasJMAS_292_19.
22. Consten EC, van Iersel JJ, Verheijen PM, Broeders IA, Wolthuis AM, D'Hoore A. Long-term outcome after laparoscopic ventral mesh rectopexy: An observational study of 919 consecutive patients. *Ann Surg.* 2015;262:742–7. <https://doi.org/10.1097/SLA.0000000000001401>.
23. Madbouly KM, Abbas KS, Hussein AM. Disappointing long-term outcomes after stapled transanal rectal resection for obstructed defecation. *World J Surg.* 2010;34:2191–6. <https://doi.org/10.1007/s00268-010-0638-6>.
24. Köhler K, Stelzner S, Hellmich G, Lehmann D, Jackisch T, Fankhänel B et al. (2012) Results in the long-term course after stapled transanal rectal resection (STARR) *Langenbecks Arch Surg* 397:771–8. <https://doi.org/10.1007/s00423-012-0920-1>.
25. Watson SJ, Loder PB, Halligan S, Bartram CI, Kamm MA, Phillips RK. Transperineal repair of symptomatic rectocele with Marlex mesh: a clinical, physiological and radiologic assessment of treatment. *J Am Coll Surg.* 1996;183(3):257–61.
26. Ferrari L, Cuinas K, Hainsworth A, Darakhshan A, Schizas A, Kelleher C, et al. Transvaginal rectocele repair for the surgical treatment of a “symptomatic” rectocele when conservative measures fail: A 12 year experience of 215 patients. *Neurogastroenterol Motil.* 2022;34(11): e14343. <https://doi.org/10.1111/nmo.14343>.
27. Balata M, Elgendy H, Emile SH, Youssef M, Omar W, Khafagy W (2020) Functional outcome and Sexual-related quality of life after transperineal versus transvaginal repair of anterior rectocele: a randomized clinical trial. *Dis Colon Rectum* :63(4):527–537. <https://doi.org/10.1097/DCR.0000000000001595>.
28. Pescatori M, Zbar AP, Ayabaca SM. Tailoring surgery for obstructed defecation syndrome to the “iceberg diagram”: Long-term results. *Surgery.* 2022;172(6):1636–41. <https://doi.org/10.1016/j.surg.2022.05.030>.
29. Picciariello A, Rinaldi M, Grossi U, Trompetto M, Graziano G, Altomare DF, et al. Time trend in the surgical management of obstructed defecation syndrome: a multicenter experience on behalf of the Italian Society of Colorectal Surgery (SICCR). *Tech Coloproctol.* 2022;26(12):963–71. <https://doi.org/10.1007/s10151-022-02705-x>.

Publisher's Note

Springer Nature remains neutral with regard to jurisdictional claims in published maps and institutional affiliations.

Ready to submit your research? Choose BMC and benefit from:

- fast, convenient online submission
- thorough peer review by experienced researchers in your field
- rapid publication on acceptance
- support for research data, including large and complex data types
- gold Open Access which fosters wider collaboration and increased citations
- maximum visibility for your research: over 100M website views per year

At BMC, research is always in progress.

Learn more biomedcentral.com/submissions

