

RESEARCH

Open Access



Long-term survival and portal vein patency with novel PVTT surgery approach in advanced HCC patients with Vp3/4 PVTT following combination therapy of TKIs and PD-1 inhibitors

Tianyu Jiao^{1,2,3,4,8†}, Haowen Tang^{2,3,4,8†}, Wenwen Zhang^{2,3,4,8†}, Bingyang Hu^{3,4,8}, Tao Wan^{3,4,8}, Yinbiao Cao^{1,2,3,4,8}, Ze Zhang^{1,2,3,4,8}, Yafei Wang⁵, Junning Cao⁶, Mengqiu Cui^{1,7} and Shichun Lu^{2,3,4,5,8*}

Abstract

Background It is controversial whether patients with hepatocellular carcinoma (HCC) with portal vein tumor thrombus (PVTT) should undergo salvage surgery following the combination therapy of tyrosine kinase inhibitors (TKIs) and programmed cell death protein 1 (PD-1) inhibitors. This study aimed to elucidate the efficiency and safety of salvage surgery following combination therapy, while also summarizing a novel surgical approach for Vp3/4 PVTT.

Methods Between April 2019 and December 2022, a consecutive series of unresectable HCC patients with PVTT who received salvage surgery following combination therapy were enrolled. Evaluation included perioperative and long-term follow-up outcomes. The complete removal of Vp3/4 PVTT was achieved using a novel surgical approach characterized by “longitudinal incision and transverse suturing” and “angle-to-straight conversion”.

Results Forty patients including 22 patients with Vp3 and 18 patients with Vp4 were included. Long-term follow-up showed similar rates of portal vein patency (Vp3: 95.5%, Vp4: 94.4%, $p=0.900$), and 3-year portal vein patency rates were 95.0%. There were no significant differences observed in combination therapy-related adverse events ($p=0.253$) and perioperative complications ($p=0.613$) between the Vp3 and Vp4 groups. The recurrence patterns were similar between the two groups ($p=0.131$). There were no significant differences in overall survival (OS) and recurrence-free (RFS) survival between the Vp3 and Vp4 groups (OS $p=0.457$, RFS $p=0.985$). Patients who achieved a pathological complete response had significantly better RFS ($p=0.011$).

Conclusion Salvage surgery after combination therapy demonstrated favorable efficacy and safety. The novel surgical approach for PVTT can effectively achieve complete removal of PVTT and ensured long-term portal vein patency.

Keywords Hepatocellular carcinoma, Portal vein tumor thrombus, Salvage surgery, Programmed cell death protein 1 inhibitors, Tyrosine kinase inhibitors

[†]Tianyu Jiao, Haowen Tang and Wenwen Zhang contributed equally contributed to this work.

*Correspondence:

Shichun Lu

lusc_301@163.com

Full list of author information is available at the end of the article



Background

Hepatocellular carcinoma (HCC) is one of the most common malignancies and a leading cause of cancer-related mortality worldwide [1]. In China, the incidence of HCC accompanied by portal vein tumor thrombus (PVTT) was reported to be 44%–62.2% [2]. According to the Barcelona Clinic Liver Cancer (BCLC) classification [3], the presence of PVTT indicates an advanced stage of HCC and is associated with therapeutic challenges and a poor prognosis [4–6], with a median overall survival (mOS) of only 6.1–11.2 months following traditional treatments [7]. These patients were regarded as unresectable in the majority of international guidelines, and systemic treatments such as programmed cell death protein 1 (PD-1) inhibitors and tyrosine kinase inhibitors (TKIs) were recommended [8–10].

Recently, the combination of atezolizumab and bevacizumab has been approved as a novel first-line treatment for unresectable HCC and has improved patient outcomes, with a mOS of 19.2 months, median progression-free survival (mPFS) of 6.8 months, and an objective response rate (ORR) of 35.4% [11, 12]. Another combination of lenvatinib and pembrolizumab for unresectable HCC also showed promising results, with a mOS of 22 months, mPFS of 9.3 months, and ORR of 46% [13]. Consequently, various treatment strategies combining TKIs and PD-1 inhibitors have been evaluated and have shown encouraging preliminary data [14]. Given the high ORR after combination therapy, a proportion of initially unresectable HCC can be converted to resectable HCC, allowing for salvage surgery [15]. Till now, certain studies with limited cases have been reported sporadically [15–21], which suggests that salvage surgery after the combination therapy may be feasible.

However, limited by the sample size of previous studies, little is known about the efficiency and safety of salvage surgery, as well as the surgical approach of PVTT. As early as 2016, the current authors initiated combination therapy based on TKIs and PD-1 inhibitors for unresectable HCC [22]. With accumulating experiences, a consensus on salvage surgery following combination therapy of PD-1 inhibitors and TKIs for advanced HCC among Chinese experts has also been reached and drafted by our team [23]. Based on our long-term clinical practice, the present study aims to report the outcomes of a cohort of patients with initially unresectable HCC with PVTT who underwent combination therapy of TKIs plus PD-1 inhibitors and salvage surgery, as well as to summarize the surgical experience, particularly in the management of PVTT.

Materials and methods

Patients

Data from a consecutive series of patients with unresectable HCC with PVTT who underwent salvage surgery after combination therapy of TKIs plus PD-1 inhibitors were analyzed. All patients met the following inclusion criteria: (1) HCC was diagnosed histologically and according to the American Association for the Study of Liver Diseases (AASLD) guidelines [8]; (2) Underwent a salvage surgery after successful combination therapy; (3) Child–Pugh score < 7; (4) BCLC stage C, with PVTT; (5) Eastern Cooperative Oncology Group performance status (ECOG PS) score ≤ 1 ; (6) expected survival ≥ 12 weeks; (7) absence of esophageal or gastric varicose bleeding events due to portal hypertension in the past 6 months; (8) at least one measurable tumor lesion by the modified Response Evaluation Criteria in Solid Tumors (mRECIST) [24]; and (9) no history of administration of any PD-1 inhibitors, TKIs, or any other immunotherapy. The Exclusion Criteria were: (1) Patients who did not respond to combination therapy; (2) Patients unwilling to undergo salvage surgery; (3) Patients without incomplete clinical, imaging, or survival data.

All patients were divided into Vp3 and Vp4 groups according to the PVTT classification. The present study was performed in accordance with the Declaration of Helsinki and was approved by the Chinese PLA General Hospital Ethics Committee (Approval No. S2018-111–01). All patients signed the written informed consent before the initiation of treatment and salvage surgery.

Combination treatment

TKIs included lenvatinib (12 mg for body weight ≥ 60 kg, and 8 mg for body weight < 60 kg, orally once a day), sorafenib (0.2 g, orally, twice a day), and apatinib (0.85 g, orally, once a day). PD-1 inhibitors were intravenously administered as follows: sintilimab (200 mg), or nivolumab (3 mg/kg), or camrelizumab (200 mg), or toripalimab (240 mg), or tislelizumab (200 mg), or pembrolizumab (200 mg), every 3 weeks as a cycle. Dose reduction or discontinuation was recommended for patients who experienced serious adverse events (AEs) according to the ASCO guideline [25].

Surgical information

The outcomes of blood tests and dynamic contrast-enhanced magnetic resonance imaging (DCE-MRI) were assessed preoperatively. Patients who were eligible for salvage surgery met the following criteria: (1) radical resection could be achieved with sufficient remnant liver volume; (2) intact or reconstructable vascular structure

of the reserved liver; (3) Child–Pugh score < 7; (4) ECOG PS score ≤ 1 ; (5) absence of severe AEs due to the combination therapy; and (6) evaluation of main tumor as completed response (CR), partial response (PR) or stable disease (SD) according to the mRECIST for at least 2 months.

In the event of postoperative recurrence, treatment options such as curative resection, radiofrequency ablation, after-line drug therapy, TACE, or best supportive treatment can be considered based on the individual patient's condition.

Pathological and radiological assessment

All tumor samples were examined by experienced hepatopathologists. In the present study, pathological complete response (pCR) was defined as no residual viable tumor cells from completely sampled tumors. The radiological assessment was performed based on patients' DCE-MRI at the baseline and every 6–8 weeks after treatment initiation. PVT T was classified according to the Vp grading system [26]. PVT T downstaging is defined as the radiographic observation of regression of PVT T. Tumor response, including CR, PR, SD was assessed according to the mRECIST [24] and evaluated by professional radiologists who were blinded to pathological results.

Follow-up

The primary endpoint was RFS, which was defined as the time from the salvage surgery to the first radiologically confirmed recurrence or death from any cause. The secondary endpoint was OS, which referred to the time from the start of treatment to death from any cause. All the included patients were treated and followed up regularly. All Patient's data were systematic collected. The combination therapy related and perioperative AEs were graded using the CTCAE (version 5.0) and the Clavien-Dindo Classification of Surgical Complications [27].

Statistical analysis

Statistical analysis was performed using SPSS 20.0 software (IBM, Armonk, NY, USA) and R 4.2.1 software. Continuous variables were expressed as median (range) and compared using the student's *t* test or the Mann–Whitney test. Categorical variables were presented as frequency (percentage) and compared using the Chi-square test or Fisher's exact test. Kaplan–Meier curves were generated for OS, RFS, and the log-rank test was used to compare between groups. Differences were considered statistically significant if the *p* value was lower than 0.05. HRs and their 95% confidence intervals (CIs) were estimated from the Cox model. The statistical power is calculated using GPower 3.1 with α set at 0.05 and β set at 0.2.

Results

Patients' baseline characteristics

A consecutive series of 40 patients (22 patients in Vp3 group, 18 patients in Vp4 group) with initially unresectable HCC and PVT T were enrolled from April 2019 to December 2022. All patients underwent salvage surgery following combination therapy of TKIs and PD-1 inhibitors.

Patients' demographic and baseline clinical characteristics are summarized in Table 1. The majority of patients with primary HCC had a background of HBV-related cirrhosis, accounting for 90.9% in Vp3 group and 83.3% in Vp4 group ($p=0.822$). There were no significant differences between the Vp3 and Vp4 groups in terms of demographic characteristics, baseline liver function, alpha-fetoprotein (AFP) levels, tumor number, size, or lymph node metastasis.

Salvage surgery after the combination therapy

The results of preoperative evaluation and surgical features are shown in Table 1. All patients met the above-mentioned criteria. The TKIs were withdrawn 7 days before surgery to minimize their influence on the surgery, while PD-1 inhibitors were continually used during the perioperative period. Preoperative AFP levels exceeding 400 ng/mL were observed in 2 patients (9.1%) in the Vp3 group and 6 patients (33.3%) in the Vp4 group, and the difference was not statistically significant ($p=0.110$). Laparotomy operation was performed in 19 patients (86.4%) in the Vp3 group and 18 patients (100%) in the Vp4 group, with no significant difference noted ($p=0.238$). The median number of preoperative drug therapy cycles was 4.5 in the Vp3 group and 5 in the Vp4 group, showing no significant distinction ($p=0.946$). Types of hepatectomy included 5 left hepatectomies, 6 right hepatectomies, and 11 segmental liver resections in the Vp3 group, while the Vp4 group consisted of 4 left hepatectomies, 8 right hepatectomies, and 6 segmental liver resections, without significant difference between the groups ($p=0.465$). The median operation time was 265.5 min in the Vp3 group and 260 min in the Vp4 group, with no statistically significant distinction ($p=0.697$). The median intraoperative blood loss was 375 mL in the Vp3 group and 575 mL in the Vp4 group, showing a marginal difference ($p=0.058$). Postoperatively, all patients in both groups achieved Child–Pugh grade A scores on the 5th day, without a significant difference observed ($p=0.377$). Both groups had no mortality during the perioperative period.

The modified surgical approach was explained with the right hemihepatectomy with right Vp4 PVT T as an example (Fig. 1). Technical details are as follows: Adequate exposure of the MPV, RPV, and LPV is crucial

Table 1 Baseline and perioperative characteristics

Characteristics	Vp3 (N=22) n (%)	Vp4 (N=18) n (%)	p value
Demographic			
Age, median (range), year	55.0 (38–67)	57.0 (31–68)	0.682
Gender (male/female)	19 (86.4)/ 3 (13.6)	14 (77.8)/4 (22.2)	0.680
Etiology, HBV, yes	20 (90.9)	15 (83.3)	0.822
Anti-viral treatment, yes	13 (59.1)	10 (55.6)	0.822
Liver cirrhosis, yes	20 (90.9)	15 (83.3)	0.642
Baseline data			
Child–Pugh score (5/6)	13 (59.1)/ 9 (40.9)	14 (77.8)/ 4 (22.2)	0.209
ECOG performance status=0, yes	22 (100.0)	17 (94.4)	0.450
Hemoglobin, median (range), g/L	137.5 (114–171)	145 (105–189)	0.189
WBC count $\times 10^9/L$, median (range)	5.62 (2.29–10.45)	5.75 (3.67–11.99)	0.276
Platelet count $\times 10^9/L$, median (range)	142 (67–327)	161 (79–312)	0.779
AFP at baseline > 400 ng/ml, yes	10 (45.5)	11 (61.1)	0.726
Tumor number (single/ multiple)	14 (63.6)/ 8 (36.4)	9 (50.0)/ 9 (50.0)	0.385
Tumor diameter > 10 cm, yes	12 (54.5)	12 (66.7)	0.436
Lymphatic metastasis, yes	4 (18.2)	7 (38.9)	0.173
Perioperative data			
AFP before surgery > 400 ng/ml, yes	2 (9.1)	6 (33.3)	0.110
Laparotomy operation	19 (86.4)	18 (100)	0.238
Treatment cycle, median (range), time	4.5 (3–23)	5 (3–9)	0.946
Types of hepatectomy (left/right/segmental)	5 (22.7)/6 (27.3)/11 (50.0)	4 (22.2)/8 (44.4)/6 (33.3)	0.465
Hospital stay after surgery, median (range), day	8.5 (5–33)	9.5 (5–20)	0.697
Surgical time, median (range), min	265.5 (178–390)	260 (180–405)	0.697
Blood loss, median (range), mL	375 (50–1000)	575 (50–3000)	0.058
Child–Pugh 5th days after surgery (5/6)	15 (68.2)/7 (31.8)	14 (77.8)/4 (22.2)	0.377

PVTT portal vein tumor thrombosis, Vp portal vein invasion, HBV hepatitis B virus, ECOG eastern cooperative oncology group, WBC white blood cell, AFP alpha-fetoprotein

(Fig. 1A). Before longitudinally incising the portal vein, it is essential to block the main portal vein and contralateral portal vein branches thoroughly (Fig. 1B). A bile duct scraper was utilized to completely extract the PVTT (Fig. 1C). Subsequently, the RPV was incised, and the incised edge was occluded (Fig. 1D). It was imperative to flush the potentially residual PVTT by gradually releasing the blockades (Fig. 1E). Subsequently, transverse suturing was performed to enlarge the inner diameter of the portal vein, preventing portal vein stenosis (Fig. 1F). Finally, the angle of the portal vein was converted to a straight configuration, maintaining hemodynamic stability and shortening the redundant portal vein (Fig. 1G).

Outcomes

Table 2 summarizes the radiological, pathological and recurrence outcomes of PVTT patients. Radiological assessment of main tumor showed similar outcomes between Vp3 and Vp4 groups ($p=0.165$): 4 CR (18.2%), 18 PR (81.8%), and 0 SD (0.0%) in Vp3 group; 2 CR (11.1%), 13 PR (72.2%), and 3 SD (16.7%) in Vp4 group.

Figure 2A illustrates a waterfall plot demonstrating the reduction of the main tumor, as evaluated by the mRECIST criteria, following combination therapy in both the Vp3 and Vp4 groups. It is worth mentioning that one patient in Vp4 group exhibited a downstaging from Vp4 to Vp3 classification of PVTT, despite the absence of significant tumor regression. As for PVTT, 8 patients (36.4%) in the Vp3 group and 7 patients (38.9%) in the Vp4 group achieved downstaging, with no significant difference observed ($p=0.870$). Figure 2C illustrates the alterations in PVTT classification before and after combination treatment in the Vp3 and Vp4 groups. Figure 2B1 shows a 51-year-old man with a 19.08 cm diameter tumor and Vp4 PVTT, and in Fig. 2B2, the tumor was reduced to 10.47 cm and PVTT down-staged into Vp3 after combination therapy.

Pathological assessment revealed that the Vp3 group had a higher rate of overall pCR rate compared to the Vp4 group (27.3% vs 22.2%, $p=0.040$). However, the rates of PVTT PCR were similar between the Vp3 and Vp4 groups (63.6% vs 61.1%, $p=0.870$). R0 resection was

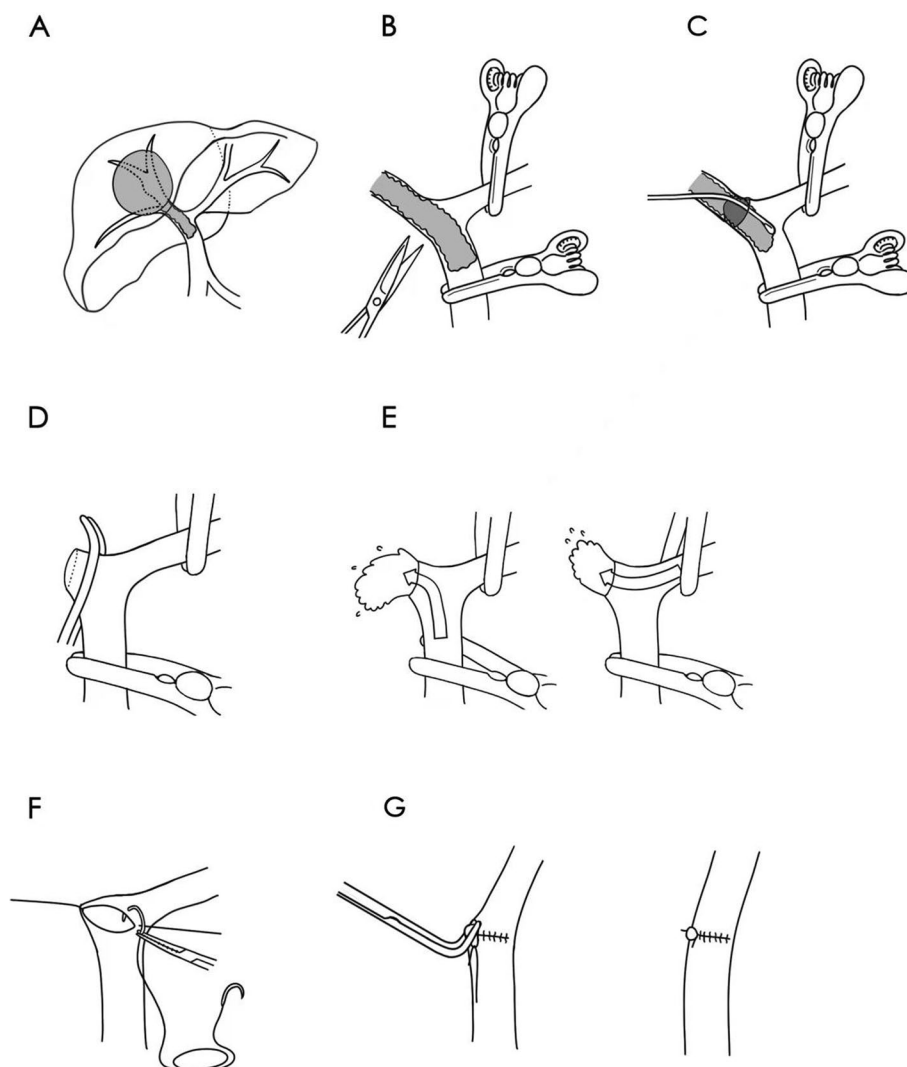


Fig. 1 Surgical approach for VP3/4 PVTT. **A** HCC with Vp4 PVTT in right hemi liver; **B** reveal the MPV, the RPV and the LPV and temporarily block the MPV and the LPV, then longitudinally dissect the RPV; **C** completely extract the PVTT; **D** cut the RPV and occlude the cut edge; **E** flush the potential residual PVTT from the RPV and the LPV; **F** transversely suture the stump; **G** convert the angle of portal vein to straight. Abbreviations: HCC Hepatocellular carcinoma, Vp portal vein invasion, PVTT portal vein tumor thrombus, MPV main portal vein, RPV right portal vein, LPV left portal vein

achieved in most cases, with only one R1 resection (5.6%) in Vp4 group ($p=0.450$).

There was no significant difference in recurrence patterns (intrahepatic vs extrahepatic vs Synchronous) between the Vp3 and Vp4 groups ($p=0.131$). Furthermore, the treatment approaches for recurrence showed similarity between the Vp3 and Vp4 groups ($p=0.444$).

Follow-up

The cut-off date for the present analysis was November 2023, and the median follow-up was 29.5 months (8–55 months). At the time of data collection, tumor recurrence was detected in 24 patients, and 9 patients

died. As illustrated in Fig. 3A, the mOS had not reached, and the 3-year OS rates after initial treatment were all 76.6%; an mRFS of 11 months could be achieved (95% CI, 2.68–19.32), and the 1- and 3-year RFS rates after salvage surgery were 72.5% and 30.7%. As illustrated in Fig. 3B, the median portal vein patency rate of all patients had not reached, and 3-year portal vein patency rates were 95.0%.

As illustrated in Fig. 3C and D, the OS and RFS stratified by the Vp classification was not significantly different (OS $P=0.457$, RFS $P=0.985$), and the mRFS of Vp3 and Vp4 patients were 10 months (95% CI, 5.403–14.597) and 17 months (95% CI, 4.00–30.00), respectively. Patients

Table 2 Outcomes of PVTT patients

Variables	Vp3 (N=22) n (%)	Vp4 (N=18) n (%)	p value
Radiological outcomes			
Radiological assessment of main tumor, per mRECIST criteria			0.165
CR	4(18.2)	2(11.1)	
PR	18(81.8)	13(72.2)	
SD	0(0.0)	3(16.7)	
Radiological PVTT downstage, yes	8(36.4)	7(38.9)	0.870
Pathological outcomes			
Overall pathological pCR response, yes	6(27.3)	4(22.2)	0.040
PVTT pathological pCR response, yes	14(63.6)	11(61.1)	0.870
R0 resection, yes	22(100.0)	17(94.4)	0.450
Recurrence outcomes			
Recurrence patterns			0.131
Intrahepatic recurrence	7(31.8)	10(55.6)	
Extrahepatic metastasis	5(22.7)	1(5.6)	
Synchronous intrahepatic and extrahepatic recurrences	1(4.5)	0(0.0)	
Recurrence treatment			0.444
Curative resection	2(9.1)	4(22.2)	
Radiofrequency ablation	3(13.6)	2(11.1)	
After-line drug therapy	3(13.6)	0(0.0)	
Best support treatment	1(4.5)	1(5.6)	
TACE + After-line drug therapy	4(18.2)	4(22.2)	

Vp portal vein invasion, mRECIST modified response evaluation criteria in solid tumors, CR complete response, R0 no residual tumor, TACE transcatheter arterial chemoembolization

with overall pCR had a longer OS ($P=0.053$) and RFS ($P=0.011$, HR=0.242, 95% CI, 0.072–0.816) (Fig. 3E and Fig. 3F), and the mRFS for patients with and without overall pCR was 37 months (95% CI, NA) and 10 months (95% CI, 7.46–12.55), respectively. It is noteworthy that no patients with overall pCR experienced death during follow-up.

Safety

The overall incidence of AEs was similar between the Vp3 and Vp4 groups, with 19 cases (86.4%) in the Vp3 group and 18 cases (100%) in the Vp4 group ($p=0.253$). Notably, no grade 4 or higher AEs occurred in either group. The differences in the incidence of grade 3 AEs between the Vp3 and Vp4 groups were not statistically significant ($p=0.486$). Among the grade 3 AEs, hypertension (5 patients in Vp3 group, 2 patients in Vp4 group) was the most common, followed by GGT increased, liver

autoimmune disorder, blood bilirubin increased, platelet count decreased, abdominal pain, myocarditis and fever (Table 3).

There was no statistically significant difference in the distribution of Clavien-Dindo scores between the Vp3 and Vp4 groups ($p=0.613$). One patient in the Vp3 group experienced a grade 4 complication, specifically pulmonary embolism, and required intensive care unit (ICU) transfer and anticoagulation therapy until full recovery. There was no significant difference in PVT occurrence between the Vp3 and Vp4 groups ($p=0.439$). In the Vp3 group, 1 patient (4.5%) had a grade 2 PVT, while in the Vp4 group, 2 patients (11.1%) had grade 1 PVT and 1 patient (5.6%) had grade 2 PVT according to the Yerdel classification [28]. Following anticoagulation therapy, all grade 1 thromboses resolved in the long term. Among the 2 patients with grade 2 PVT, they showed a gradual progression towards portal cavernoma formation.

(See figure on next page.)

Fig. 2 Summary of pathological and radiological evaluation. **A** The waterfall plot of main tumor reduction after combination therapy. **B1** A 51-year-old man with a 19.08 cm diameter tumor that contained multiple enhanced lesions and Vp4 PVTT before combination therapy; **B2** after combination therapy, the tumor was reduced to 10.47 cm with a complete response of enhanced lesions and PVTT downstaged into Vp3. **C** The waterfall plot of the PVTT classification before and after combination therapy based on radiological evaluation. Abbreviations: PVTT portal vein tumor thrombosis, Vp portal vein invasion

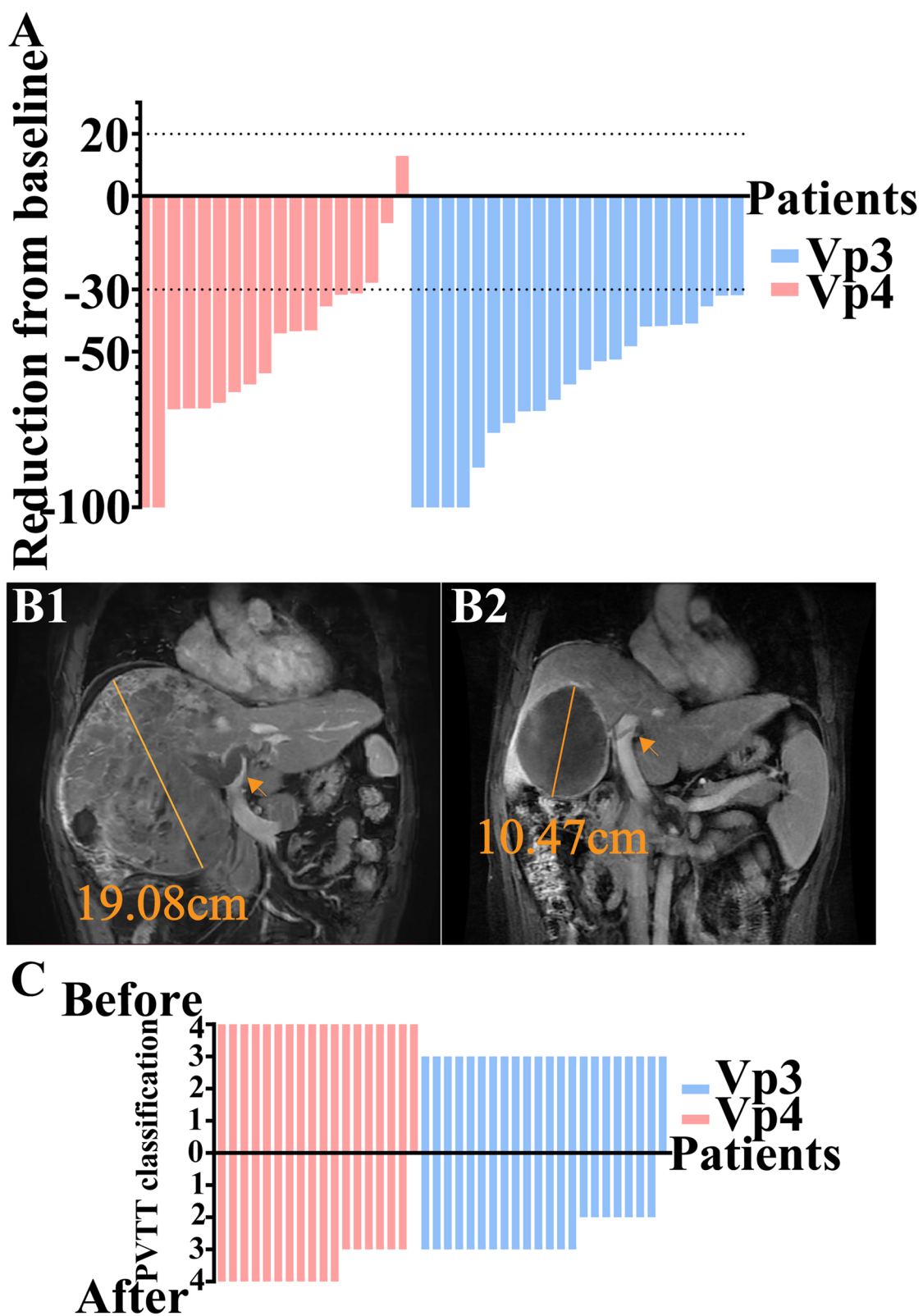


Fig. 2 (See legend on previous page.)

However, they also developed robust collateral circulation and maintained well liver function without any symptoms. Notably, the long-term portal vein patency rates were 95.5% in the Vp3 group and 94.4% in the Vp4 group, with no significant difference observed ($p=0.704$). No life-threatening AEs or perioperative complications were observed in either group, and they were effectively managed.

Discussion

To date, few studies have concentrated on patients with HCC and PVTT receiving salvage surgery following combination treatment of TKIs and PD-1 inhibitors. In the present study, we reported the outcomes of 40 patients with initial unresectable HCC with VP3/4 PVTT who underwent salvage surgery following successful combination therapy, as well as the surgical experience of Vp3/4 PVTT. These findings were consistent with previous studies. Our team previously reported 35 HCC patients with major vascular invasion accepted the combination therapy, of whom 14 patients were converted successfully and underwent salvage surgery without postoperative mortality [16], and we also reported a pilot study of 10 patients who underwent salvage surgery after the combination therapy [18]. Moreover, Zhu et al. [19] conducted a cohort study on 101 patients with advanced HCC, and 24 patients underwent salvage surgery after combination treatment. Also, Yang et al. [20] and Zhu et al. [21] both reported treating a small group of patients with this treatment approach. These studies emphasize the importance of further research to fully comprehend the characteristics of salvage surgery following combination therapy.

It is controversial whether patients with PVTT could benefit from surgery. To date, a growing body of evidence demonstrated that surgery is beneficial for selected patients with PVTT. A multicentric study from Italy compared surgery vs sorafenib for BCLC C patients and found that liver resection was followed by better OS ($p<0.001$) and PFS ($p=0.007$) [29]. In a systematic review conducted by Glantzounis et al. [30], 3 659 patients with PVTT from 29 studies were assessed, and the mOS and 3-year survival rate were 15 months and 33%. Kokudo et al. [31] analyzed 6 474 patients with PVTT, and it was found that the mOS in surgery group was 1.77 years

longer than that in non-surgery group ($p<0.001$), while this finding was not observed in patients with Vp4 PVTT. The mOS and mRFS of patients with Vp4 PVTT in the surgery group were 0.91 years (95% CI, 0.75–1.23) and 0.38 years (95% CI, 0.29–0.45). Moreover, Wang et al. [32] performed a multi-center study in China, and a total of 1 580 patients with PVTT were analyzed. According to the Cheng et al.'s classification, the mOS of patients who underwent surgery were 15.9 months (type I), 12.5 months (type II), and 6 months (type III), respectively, and surgery was found as the best treatment for patients whose PVTT did not reach the MPV. In summary, these studies showed that direct surgery can only offer limited survival benefits to patients with Vp4 whose outcome is the worst. The present study found that the mOS of patients with Vp4 PVTT after combination therapy was significantly longer compared to previous studies and even comparable to Vp3 patients.

The selection of the appropriate surgical strategy should be based on the location of PVTT [2, 33, 34]. For PVTT cases that are limited to the resection line (Vp1-2), segmental resection or hemi-hepatectomy is considered to be a viable treatment option. If PVTT that extends to or beyond the bifurcation (Vp3-4), en bloc resection with portal vein reconstruction or thrombectomy is recommended. However, the optimal method for Vp3-4 PVTT remains a topic of debate [35, 36]. Chok et al. [37] compared the outcomes of en bloc resection plus portal vein reconstruction and thrombectomy in patients with Vp4 PVTT and found that the mOS (9.4 months vs. 8.58 months), mRFS (3.78 months vs. 1.51 months), and recurrence patterns were comparable. Therefore, to minimize the surgical risk, thrombectomy was chosen in this study. In the suturing of the portal vein after thrombectomy, the conventional thrombectomy choosing either the closure of the stump or end-to-end anastomosis to seal the portal vein incision [35, 36, 38]. This can leave an angled closure at the suture site, causing alterations in the hemodynamics within the portal vein. Taking into consideration the above factors, a novel surgical approach was employed for Vp3/4 PVTT (Fig. 1). We summarized the key aspects of the approach as "longitudinal incision and transverse suturing" and "angle-to-straight conversion". Compared with conventional

(See figure on next page.)

Fig. 3 Survival analysis of Vp3/4 PVTT patients who received salvage surgery following combination therapy of TKIs and PD-1 inhibitors. **A** Overall survival and Recurrence-free survival of all cohort: the mOS had not reached, and the mRFS was 11 months (95% CI, 2.68–19.32). **B** the 3-year portal vein patency rates of all patients were 95.0%. **C** Overall survival stratified by the Vp classification ($P=0.457$). **D** Recurrence-free survival stratified by the Vp classification ($P=0.985$). **E** Overall survival stratified by overall pCR ($P=0.053$). **F** Recurrence-free survival stratified by overall pCR ($P=0.011$). Abbreviations: PVTT portal vein tumor thrombosis, Vp portal vein invasion, mOS median overall survival, mPFS median progression-free survival; pCR pathological complete response

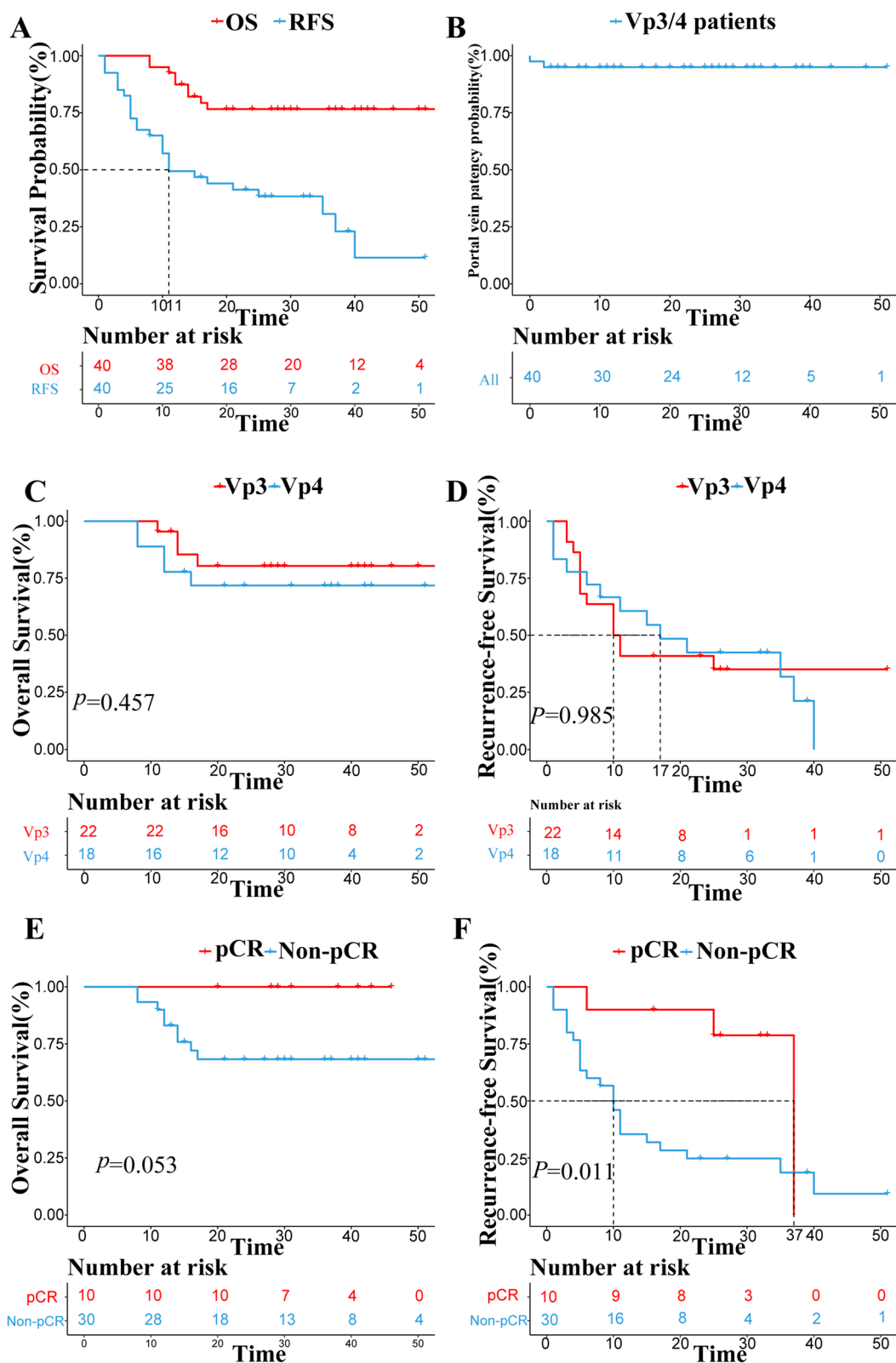


Fig. 3 (See legend on previous page.)

Table 3 Combination therapy related AEs and perioperative complications

Adverse events	Vp3 (N=22) n (%)	Vp4 (N=18) n (%)	p value
Combination therapy related AEs			
All AEs, yes	19 (86.4)	18 (100)	0.253
Grade 3 AEs			0.486
Hypertension	5 (22.7)	2 (11.1)	
GGT increased	1 (4.5)	2 (11.1)	
Liver autoimmune disorder	0 (0.0)	1 (5.6)	
Blood bilirubin increased	0 (0.0)	1 (5.6)	
Platelet count decreased	0 (0.0)	1 (5.6)	
Abdominal pain	0 (0.0)	1 (5.6)	
Myocarditis	1 (4.5)	0 (0.0)	
Fever	0 (0.0)	1 (5.6)	
Perioperative complications			
Clavien-Dindo score			0.613
No or I or II	18 (81.8)	17 (94.4)	
IIIa	3 (13.6)	1 (5.6)	
IV	1 (4.5)	0 (0.0)	
PVT classification			0.439
No PVT	21 (95.5%)	15 (83.3%)	
Grade 1	0 (0.0)	2 (11.1%)	
Grade 2	1 (4.5%)	1 (5.6%)	
Long-term portal vein patency, yes	21(95.5)	17(94.4)	0.704

Vp portal vein invasion, AEs adverse events, GGT Gamma-glutamyl transpeptidase

PVTT thrombectomy, [35, 36, 38] this novel approach offers the following advantages: (1) PVTT following combination therapy has undergone thorough organization, reducing the likelihood of adhesion to the portal vein wall, making resection less challenging. (2) After downstaging, the resection scope is significantly reduced, with some Vp4 cases downstaged to Vp3, eliminating the need to address the MPV. (3) "Longitudinal incision and transverse suturing" effectively mitigate portal vein c problems, while "angle-to-straight conversion" further reduces the risk of PVT. In the present study, the 3-year portal vein patency rates were up to 95.0%, the modified surgical approach can complete removal of PVTT and ensures long-term patency of the portal vein. Additionally, this approach presents some potential challenges: a considerable amount of experience in vascular surgery is required for the anatomy of the hepatic hilum, the portal vein suturing technique and the conversion of the portal vein angle.

There are several special challenges of the salvage surgery following combination therapy that are summarized as follows: (1) The administration of TKIs, which are VEGFR blockers, may increase the risk of perioperative bleeding and prolong the surgical incision healing period [21]. To mitigate these risks, TKIs were stopped 7 days prior to surgery. (2) an immune-related inflammation in

the liver could be induced by PD-1 inhibitors, making it more fragile [21]; (3) the size of tumor was relatively huge and remnant liver volume was close to the extreme. Thus, the definition of tumor resection margin may not be suitable for radical resection and an open surgery is approach preferable; 4) The occurrence of portal vein thrombosis is relatively high, so it's important to regularly detect any complications as early as possible. In our study, there was no mortality during perioperative period, indicating that this treatment strategy is relatively safe.

Patients with pCR are strongly accompanied with a longer OS and RFS, which is consistent with previously reported results [19, 39, 40]. Zhu et al. [19] reported that 24 patents received salvage surgery after combination treatment, and among them, 10 patients achieved pCR, who had a favorable RFS compared to patients with non-pCR. Furthermore, Allard et al. [40] found that survival was longer in patients who had less than 10% of viable cancer cells remaining, which may refer to the Major pathological response (MPR) of HCC. However, the findings regarding MPR as a predictor of survival in HCC are still unknown, and additional research is needed.

However, there are several limitations in the present study. First, the retrospective study design and a relatively small sample size might limit the levels of evidence, but a trend has been identified in the advantages

of this novel approach. Second, the follow-up period was not long enough to calculate mOS and 5-year survival rate. Third, this study may have some potential biases (such as excluding non-responsive patients, or those who voluntarily abandoned surgery, being a single-center study, and comprising entirely Han Chinese individuals) and confounding factors (such as the lack of complete uniformity in the combined treatment, variations in the extent of liver, and the absence of blinding). Despite implementing measures such as ensuring all surgeries were performed by the same surgeon and making efforts to collect comprehensive imaging and follow-up data to mitigate the impact of these limitations, they may still affect the generalizability of the results. Hence, multi-center, double-blind, randomized studies with a larger sample size and different races are required to further clarify the therapeutic efficacy of combination therapy and salvage surgery.

Conclusions

In summary, these outcomes suggested that the combination therapy of TKIs plus PD-1 inhibitors is an effective and safe treatment strategy for patients with PVTT; the modified surgical approach enables complete removal of PVTT and ensures long-term patency of the portal vein; following this treatment strategy, patients of Vp4 group can also achieve comparable outcomes to those of Vp3 patients. Finally, it is worth noting that further research should aim to identify accurate non-invasive biomarkers for the dynamic assessment of tumor and PVTT necrosis. This will guide us in selecting the most appropriate timing for salvage surgery.

Abbreviations

HCC	Hepatocellular carcinoma
PVTT	Portal vein tumor thrombus
BCLC classification	The Barcelona Clinic Liver Cancer classification
mOS	Median overall survival
PD-1 inhibitors	Programmed cell death protein 1 inhibitors
TKIs	Tyrosine kinase inhibitors
mPFS	Median progression-free survival
ORR	Objective response rate
AASLD	The American Association for the Study of Liver Diseases
ECOG PS score	Eastern Cooperative Oncology Group performance status score
mRECIST	The modified Response Evaluation Criteria in Solid Tumors
DCE-MRI	Dynamic contrast-enhanced magnetic resonance imaging
CR	Completed response
PR	Partial response
SD	Stable disease
pCR	Pathological complete response
AFP	Alpha-fetoprotein
MPV	Main portal vein
RPV	Right portal vein
LPV	Left portal vein

Acknowledgements

We thank patients and their families who participated in this research and appreciate Dr. Wenting Chen for his proofreading of the manuscript. We also thank Kedong Ma for his beautiful and concise diagram of the surgical approach.

Authors' contributions

TYJ, HWT, WWZ, SCL conceived and designed the study. TYJ, YBC, YFW, BYH, TW, JNC collected the data. TYJ, ZZ performed the statistical analysis and created the figures and tables in the study. MQC participated in the evaluation of radiological data. TYJ drafted the initial manuscript. TYJ, HWT, WWZ, SCL, TW participated in the manuscript revision. All authors read and approved the final manuscript. TYJ, HWT and WWZ equally contributed to the article.

Funding

None.

Availability of data and materials

The datasets analyzed during the current study are not publicly available due to protecting patient privacy, but are available from the corresponding author on reasonable request.

Declarations

Ethics approval and consent to participate

The present study was performed in accordance with the Declaration of Helsinki and was approved by the Chinese PLA General Hospital Ethics Committee (Approval No. S2018-111-01). All patients signed the written informed consent before the initiation of treatment and salvage surgery.

Consent for publication

Not applicable.

Competing interests

The authors declare no competing interests.

Author details

¹Medical School of Chinese PLA, Beijing, China. ²Faculty of Hepato-Pancreato-Biliary Surgery, the First Medical Centre, Chinese PLA General Hospital, Beijing, China 100853. ³Institute of Hepatobiliary Surgery of Chinese PLA, Beijing, China. ⁴Key Laboratory of Digital Hepatobiliary Surgery, PLA, Beijing, China. ⁵Nankai University School of Medicine, Tianjin, China. ⁶Organ Transplantation Center, The Affiliated Hospital of Qingdao University, No. 59 Haier Road, Qingdao, Shandong, China. ⁷Department of Radiology, the First Medical Centre, Chinese PLA General Hospital, Beijing, China. ⁸Faculty of Hepato-Pancreato-Biliary Surgery, Chinese PLA General, Beijing, China.

Received: 15 July 2023 Accepted: 8 December 2023

Published online: 19 December 2023

References

- Vogel A, Meyer T, Sapisochin G, Salem R, Saborowski A. Hepatocellular carcinoma. *Lancet*. 2022;400(10360):1345–62.
- Sun J, Guo R, Bi X, Wu M, Tang Z, Lau WY, Zheng S, Wang X, Yu J, Chen X, et al. Guidelines for Diagnosis and Treatment of Hepatocellular Carcinoma with Portal Vein Tumor Thrombus in China (2021 Edition). *Liver Cancer*. 2022;11(4):315–28.
- Reig M, Forner A, Rimola J, Ferrer-Fàbrega J, Burrel M, Garcia-Criado Á, Kelley RK, Galle PR, Mazzaferro V, Salem R, et al. BCLC strategy for prognosis prediction and treatment recommendation: The 2022 update. *J Hepatol*. 2022;76(3):681–93.
- Kawagishi N. HCC with portal vein tumor thrombosis: how to manage? *Hepatol Int*. 2020;14(5):609–11.
- Lu J, Zhang XP, Zhong BY, Lau WY, Madoff DC, Davidson JC, Qi X, Cheng SQ, Teng GJ. Management of patients with hepatocellular carcinoma and portal vein tumour thrombosis: comparing east and west. *Lancet Gastroenterol Hepatol*. 2019;4(9):721–30.

6. Zhang ZM, Lai EC, Zhang C, Yu HW, Liu Z, Wan BJ, Liu LM, Tian ZH, Deng H, Sun QH, et al. The strategies for treating primary hepatocellular carcinoma with portal vein tumor thrombus. *Int J Surg*. 2015;20:8–16.
7. Giannini EG, Bucci L, Garuti F, Brunacci M, Lenzi B, Valente M, Caturelli E, Cabibbo G, Piscaglia F, Virdone R, et al. Patients with advanced hepatocellular carcinoma need a personalized management: A lesson from clinical practice. *Hepatology*. 2018;67(5):1784–96.
8. Heimbach JK, Kulik LM, Finn RS, Sirlin CB, Abecassis MM, Roberts LR, Zhu AX, Murad MH, Marrero JA. AASLD guidelines for the treatment of hepatocellular carcinoma. *Hepatology*. 2018;67(1):358–80.
9. Liver EAftSot. EASL Clinical Practice Guidelines: Management of hepatocellular carcinoma. *J Hepatol*. 2018;69(1):182–236.
10. Tang H, Yong H, Duan W, Li C, Dong J. A concise review of current guidelines for the clinical management of hepatocellular carcinoma in Asia. *Transl Cancer Res*. 2017;6(6):1214–25.
11. Finn RS, Qin S, Ikeda M, Galle PR, Ducreux M, Kim TY, Kudo M, Breder V, Merle P, Kaseb AO, et al. Atezolizumab plus Bevacizumab in Unresectable Hepatocellular Carcinoma. *N Engl J Med*. 2020;382(20):1894–905.
12. Finn RS, Qin S, Ikeda M, Galle PR, Ducreux M, Kim TY, Lim HY, Kudo M, Breder V, Merle P, et al. IMbrave150: Updated overall survival (OS) data from a global, randomized, open-label phase III study of atezolizumab (atezo) + bevacizumab (bev) versus sorafenib (sor) in patients (pts) with unresectable hepatocellular carcinoma (HCC). *J Clin Oncol*. 2021;39(3_suppl):267–267.
13. Finn RS, Ikeda M, Zhu AX, Sung MW, Baron AD, Kudo M, Okusaka T, Kobayashi M, Kumada H, Kaneko S, et al. Phase Ib Study of Lenvatinib Plus Pembrolizumab in Patients With Unresectable Hepatocellular Carcinoma. *J Clin Oncol*. 2020;38(26):2960–70.
14. Liu ZL, Liu JH, Staiculescu D, Chen J. Combination of molecularly targeted therapies and immune checkpoint inhibitors in the new era of unresectable hepatocellular carcinoma treatment. *Ther Adv Med Oncol*. 2021;13:17588359211018026.
15. Huang C, Zhu XD, Shen YH, Wu D, Ji Y, Ge NL, Chen LL, Tan CJ, Zhou J, Fan J, et al. Organ specific responses to first-line lenvatinib plus anti-PD-1 antibodies in patients with unresectable hepatocellular carcinoma: a retrospective analysis. *Biomark Res*. 2021;9(1):19.
16. Zhang W, Hu B, Han J, Wang H, Wang Z, Ye H, Ma G, Chen M, Cai S, Wang X, et al. A real-world study of PD-1 inhibitors combined with TKIs for HCC with major vascular invasion as the conversion therapy: A prospective, non-randomized, open-label cohort study. *Ann Oncol*. 2020;31(Supplement 6):S1307.
17. Tsai HM, Han MZ, Lin YJ, Chang TT, Chen CY, Cheng PN, Chuang CH, Wu IC, Chen PJ, Kang JW, et al. Real-world outcome of immune checkpoint inhibitors for advanced hepatocellular carcinoma with macrovascular tumor thrombosis. *Cancer Immunol Immunother*. 2021;70(7):1929–37.
18. Zhang W, Hu B, Han J, Wang Z, Ma G, Ye H, Yuan J, Cao J, Zhang Z, Shi J et al. Surgery After Conversion Therapy With PD-1 Inhibitors Plus Tyrosine Kinase Inhibitors Are Effective and Safe for Advanced Hepatocellular Carcinoma: A Pilot Study of Ten Patients. *Front Oncol* 2021, 11.
19. Zhu XD, Huang C, Shen YH, Xu B, Ge NL, Ji Y, Qu XD, Chen L, Chen Y, Li ML et al: Hepatectomy After Conversion Therapy Using Tyrosine Kinase Inhibitors Plus Anti-PD-1 Antibody Therapy for Patients with Unresectable Hepatocellular Carcinoma. *Ann Surg Oncol* 2022.
20. Yang X, Xu H, Zuo B, Yang X, Bian J, Long J, Wang D, Zhang J, Ning C, Wang Y, et al. Downstaging and resection of hepatocellular carcinoma in patients with extrahepatic metastases after stereotactic therapy. *Hepatobiliary Surg Nutr*. 2021;10(4):434–42.
21. Zhu XD, Huang C, Shen YH, Ji Y, Ge NL, Qu XD, Chen L, Shi WK, Li ML, Zhu JJ, et al. Downstaging and Resection of Initially Unresectable Hepatocellular Carcinoma with Tyrosine Kinase Inhibitor and Anti-PD-1 Antibody Combinations. *Liver Cancer*. 2021;10(4):320–9.
22. Tang H, Cao Y, Jian Y, Li X, Li J, Zhang W, Wan T, Liu Z, Tang W, Lu S. Conversion therapy with an immune checkpoint inhibitor and an antiangiogenic drug for advanced hepatocellular carcinoma: A review. *Biosci Trends*. 2022;16(2):130–41.
23. Lu S, Cai J, Prevention PCF, Hepatobiliary Co, Association PDoCPM, Cancer C, Surgery EBoCJoH: Chinese expert consensus on conversion therapy of immune checkpoint inhibitors combined antiangiogenic targeted drugs for advanced hepatocellular carcinoma (2021 Edition). 2021.
24. Lencioni R, Llovet JM. Modified RECIST (mRECIST) assessment for hepatocellular carcinoma. *Semin Liver Dis*. 2010;30(1):52–60.
25. Schneider BJ, Naidoo J, Santomaso BD, Lacchetti C, Adkins S, Anadkat M, Atkins MB, Brassil KJ, Caterino JM, Chau I, et al. Management of Immune-Related Adverse Events in Patients Treated With Immune Checkpoint Inhibitor Therapy: ASCO Guideline Update. *J Clin Oncol*. 2021;39(36):4073–126.
26. Kudo M, Kawamura Y, Hasegawa K, Tateishi R, Kariyama K, Shiina S, Toyoda H, Imai Y, Hiraoka A, Ikeda M, et al. Management of Hepatocellular Carcinoma in Japan: JSH Consensus Statements and Recommendations 2021 Update. *Liver Cancer*. 2021;10(3):181–223.
27. Clavien PA, Barkun J, de Oliveira ML, Vauthey JN, Dindo D, Schulick RD, de Santibañes E, Pekolj J, Slankamenac K, Bassi C, et al. The Clavien-Dindo classification of surgical complications: five-year experience. *Ann Surg*. 2009;250(2):187–96.
28. Yerdel MA, Gunson B, Mirza D, Karayalçin K, Olliff S, Buckels J, Mayer D, McMaster P, Pirenne J. Portal vein thrombosis in adults undergoing liver transplantation: risk factors, screening, management, and outcome. *Transplantation*. 2000;69(9):1873–81.
29. Famularo S, Donadon M, Cipriani F, Giuliante F, Ferri S, Celsa C, Ferrero A, Foschi FG, Baiocchi GL, Biasini E et al: Hepatectomy Versus Sorafenib in Advanced Non-Metastatic Hepatocellular Carcinoma: A Real-Life Multi-centric Weighted Comparison. *Ann Surg* 2022.
30. Glantzounis GK, Paliouras A, Stylianidi MC, Milionis H, Tzimas P, Roukos D, Pentheroudakis G, Felekouras E. The role of liver resection in the management of intermediate and advanced stage hepatocellular carcinoma. A systematic review. *Eur J Surg Oncol*. 2018;44(2):195–208.
31. Kokudo T, Hasegawa K, Matsuyama Y, Takayama T, Izumi N, Kadota M, Kudo M, Ku Y, Sakamoto M, Nakashima O, et al. Survival benefit of liver resection for hepatocellular carcinoma associated with portal vein invasion. *J Hepatol*. 2016;65(5):938–43.
32. Wang K, Guo WX, Chen MS, Mao YL, Sun BC, Shi J, Zhang YJ, Meng Y, Yang YF, Cong WM, et al. Multimodality Treatment for Hepatocellular Carcinoma With Portal Vein Tumor Thrombus: A Large-Scale, Multi-center, Propensity Matching Score Analysis. *Medicine (Baltimore)*. 2016;95(11):e3015.
33. Wang JC, Xia AL, Xu Y, Lu XJ. Comprehensive treatments for hepatocellular carcinoma with portal vein tumor thrombosis. *J Cell Physiol*. 2019;234(2):1062–70.
34. Luo F, Li M, Ding J, Zheng S. The Progress in the Treatment of Hepatocellular Carcinoma With Portal Vein Tumor Thrombus. *Front Oncol*. 2021;11:635731.
35. Peng SY, Wang XA, Huang CY, Li JT, Hong DF, Wang YF, Xu B. Better surgical treatment method for hepatocellular carcinoma with portal vein tumor thrombus. *World J Gastroenterol*. 2018;24(40):4527–35.
36. Chan SL, Chong CC, Chan AW, Poon DM, Chok KS. Management of hepatocellular carcinoma with portal vein tumor thrombosis: Review and update at 2016. *World J Gastroenterol*. 2016;22(32):7289–300.
37. Chok KS, Cheung TT, Chan SC, Poon RT, Fan ST, Lo CM. Surgical outcomes in hepatocellular carcinoma patients with portal vein tumor thrombosis. *World J Surg*. 2014;38(2):490–6.
38. Ban D, Shimada K, Yamamoto Y, Nara S, Esaki M, Sakamoto Y, Kosuge T. Efficacy of a hepatectomy and a tumor thrombectomy for hepatocellular carcinoma with tumor thrombus extending to the main portal vein. *J Gastrointest Surg*. 2009;13(11):1921–8.
39. Agopian VG, Morshedi MM, McWilliams J, Harlander-Locke MP, Markovic D, Zarrinpar A, Kaldas FM, Farmer DG, Yersiz H, et al. Complete pathological response to pretransplant locoregional therapy for hepatocellular carcinoma defines cancer cure after liver transplantation: analysis of 501 consecutively treated patients. *Ann Surg*. 2015;262(3):536–45 discussion 543–535.
40. Allard MA, Sebah M, Ruiz A, Guettier C, Paule B, Vibert E, Cunha AS, Cherqui D, Samuel D, Bismuth H, et al. Does pathological response after transarterial chemoembolization for hepatocellular carcinoma in cirrhotic patients with cirrhosis predict outcome after liver resection or transplantation? *J Hepatol*. 2015;63(1):83–92.

Publisher's Note

Springer Nature remains neutral with regard to jurisdictional claims in published maps and institutional affiliations.